

OCT interpretation

AMEEN MARASHI, M.D .

RETINA SPECIALIST, OWNER OF MARASHI EYE CLINIC GROUP AND EDITOR IN ADVANCES IN OPHTHALMOLOGY & VISUAL SYSTEM AND OPEN ACCESS JOURNAL OF OPHTHALMOLOGY (OAJO)

INVENTOR OF ARTIFICIAL INTELLIGENCE RETINAL ASSISTANT MODULE WWW.AMRETINA.TK

OCT- Macular Scan Types

Tomography (Qualitative (

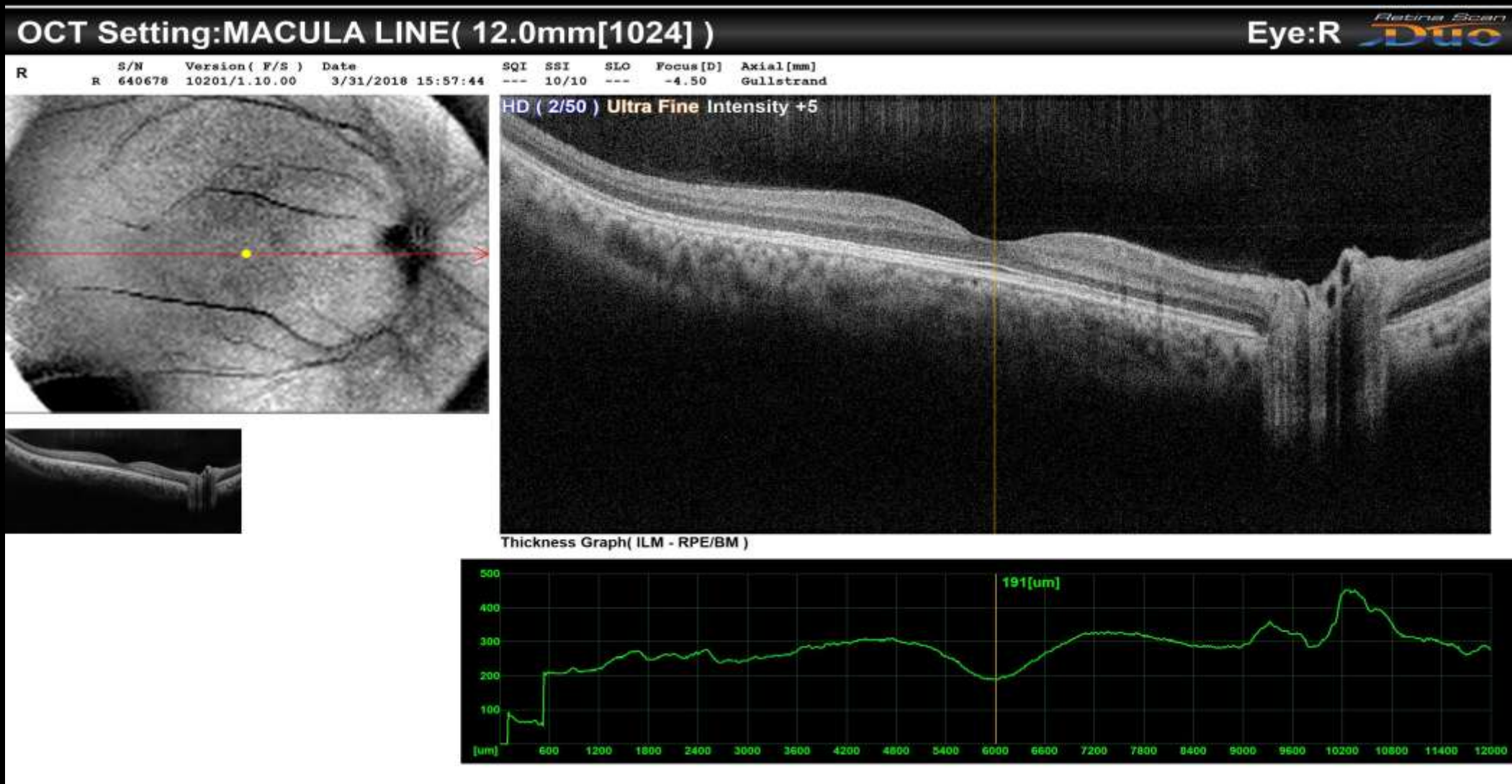
- Macular Line or B-scan
- Macular Radial
- Macular Multi or Raster

Topography (Quantitative(

- Macular Map and 3D
- Enface OCT (C-scan(
- OCT angiography

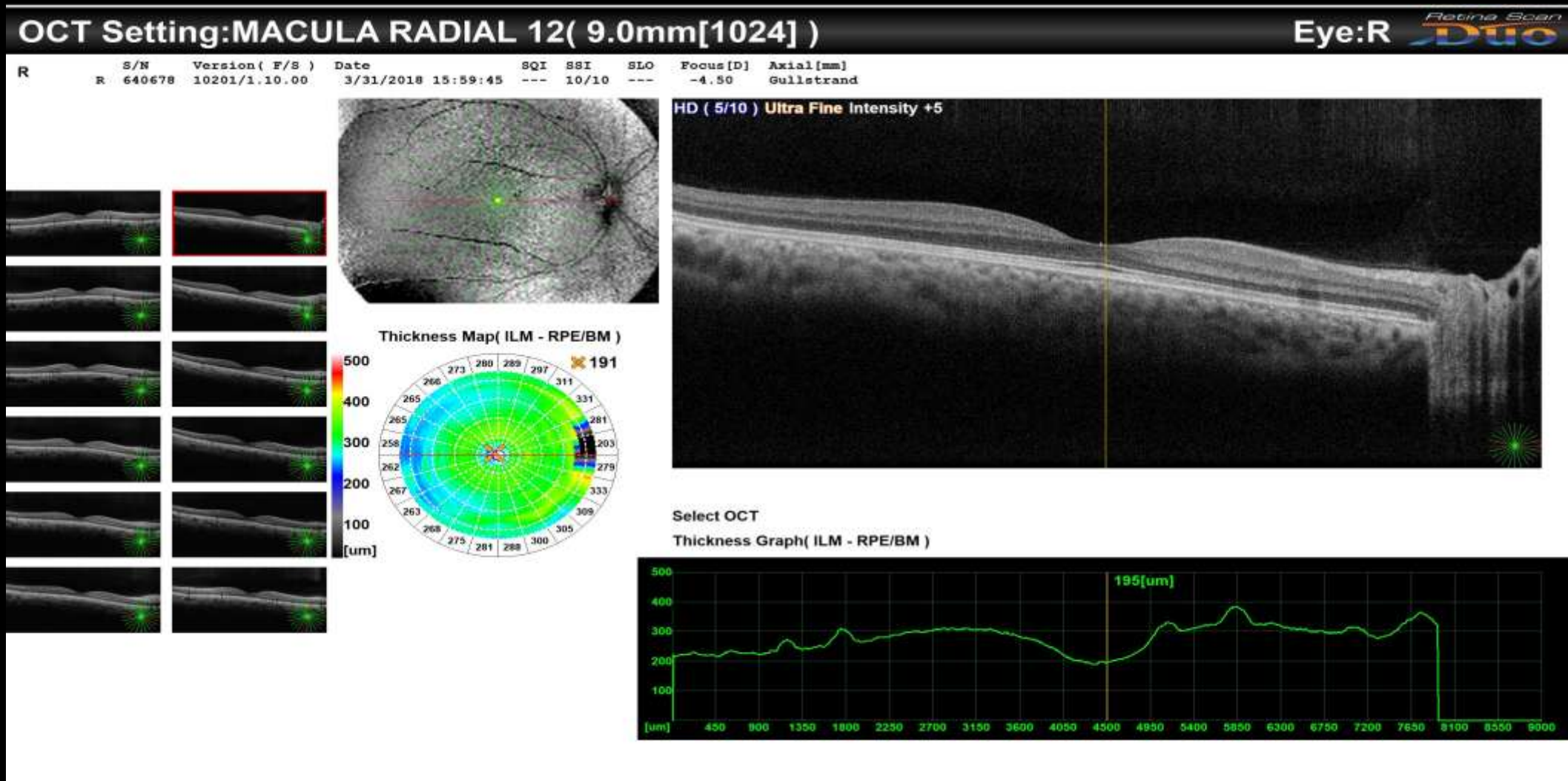
OCT- Macular Scan Types

Tomography-Macular Line or B-scan



OCT- Macular Scan Types

Tomography-Macular Radial



OCT- Macular Scan Types

Tomography-Macular Multi or RASTER

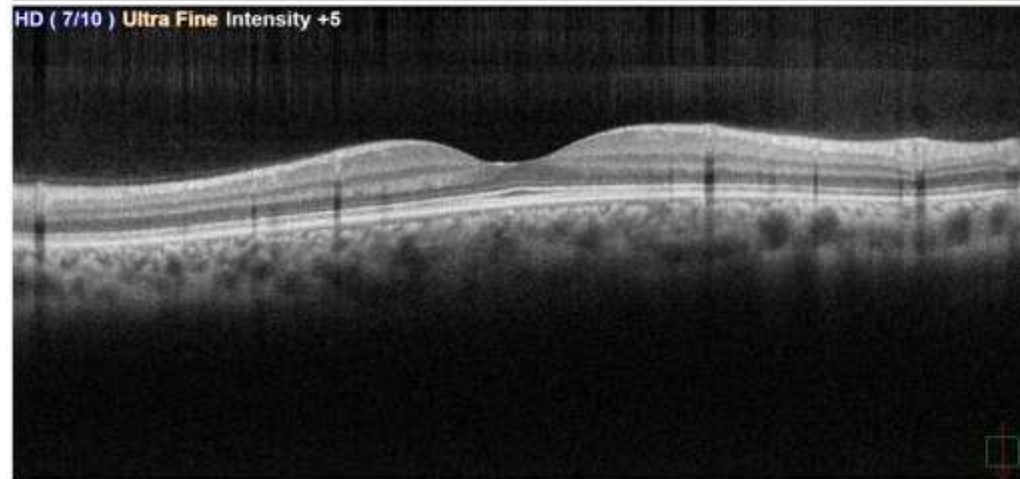
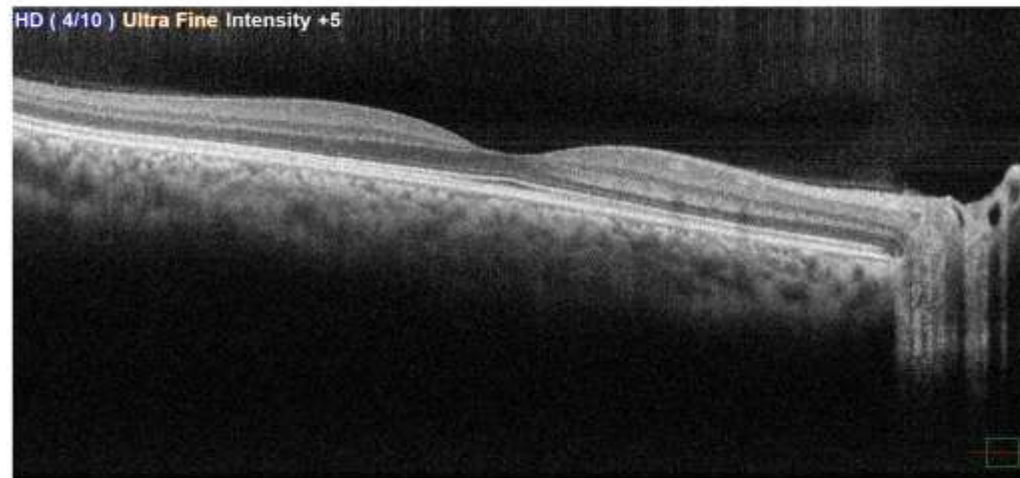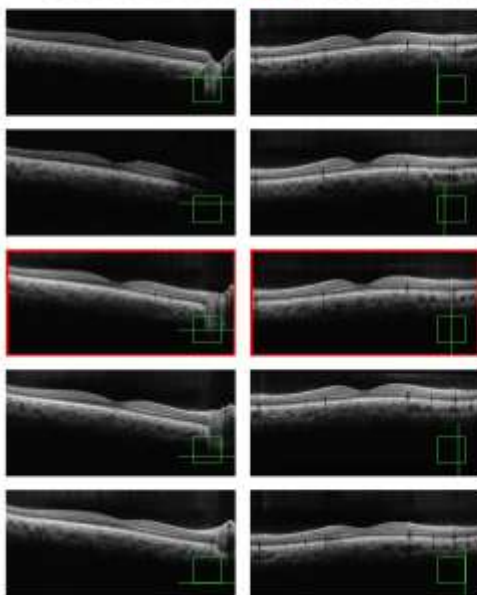
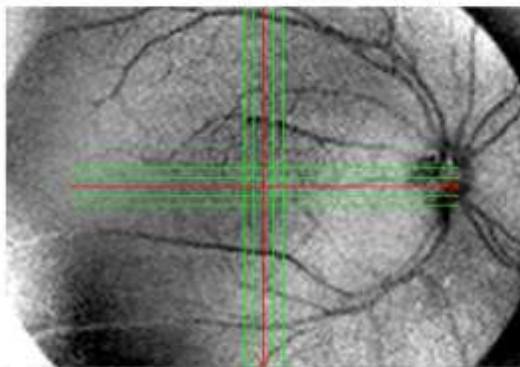
OCT Setting:MACULA MULTI CROSS(9.0mm[1024], Pitch=0.225mm)

Eye:R

Retina Scan Duo

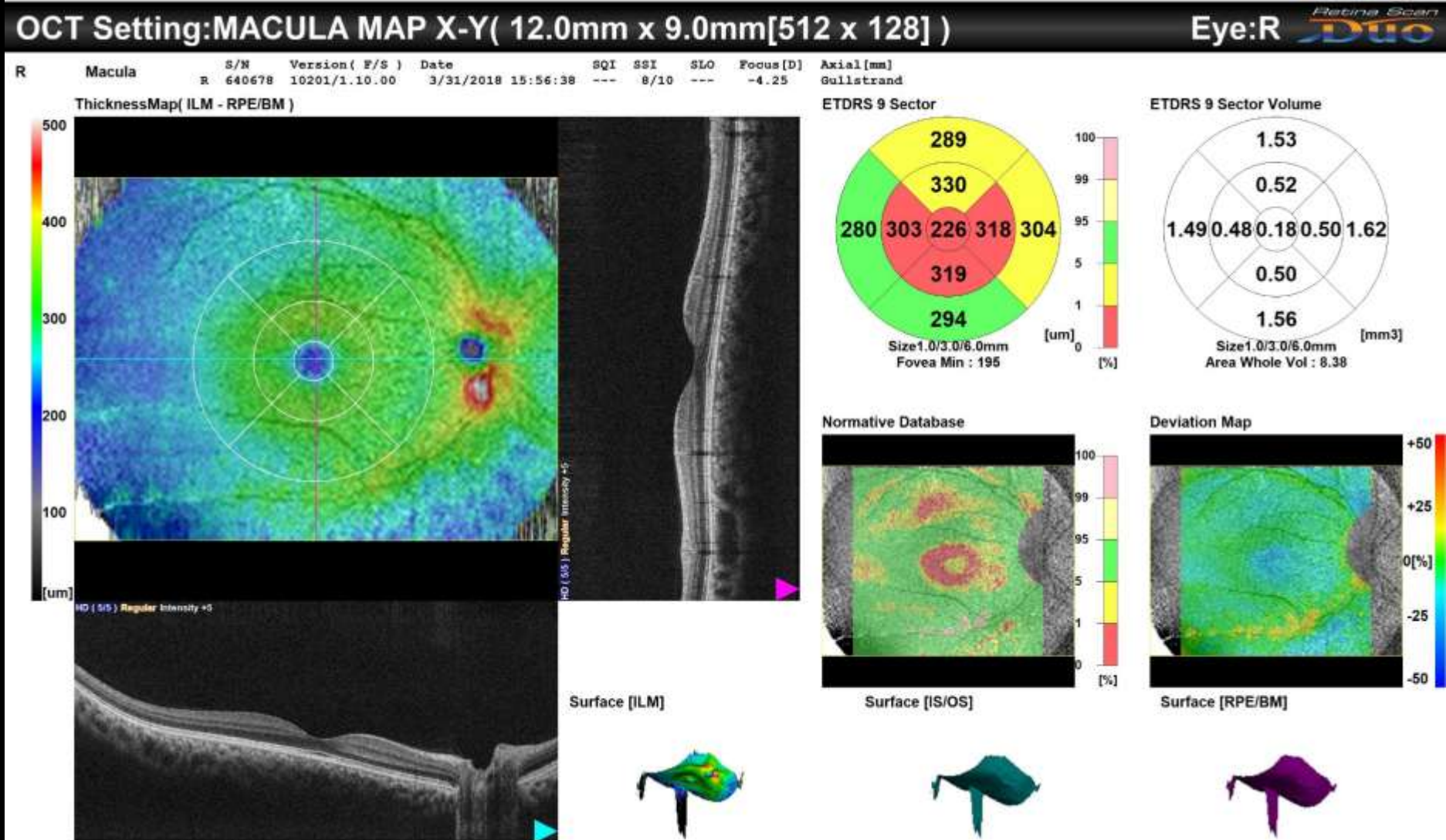
R

S/N	Version(F/S)	Date	SQI	SSI	SLO	Focus[D]	Axial[mm]
R 640678	10201/1.10.00	3/31/2018 15:59:04	---	10/10	---	-4.50	Gullstrand



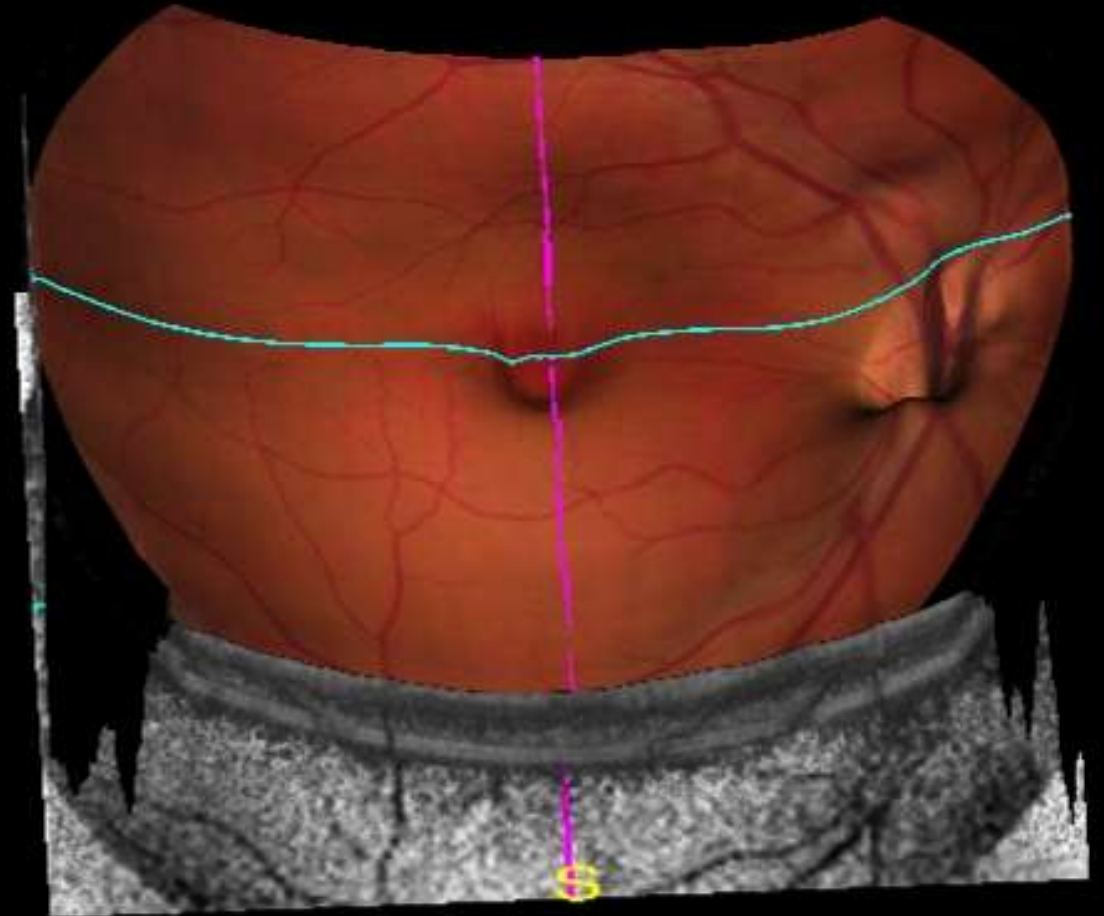
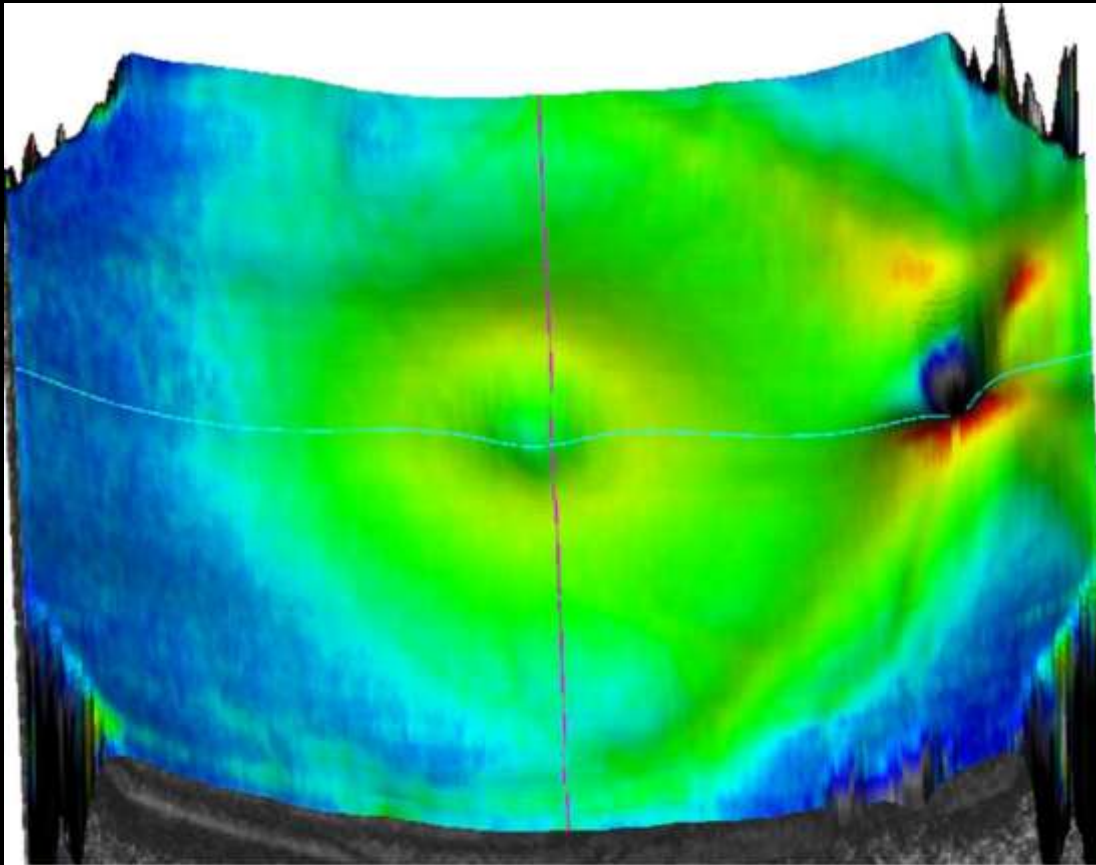
OCT- Macular Scan Types

Topography-Macular Map



OCT- Macular Scan Types

Topography-Macular 3D



OCT- Macular Scan Types

Topography- Enface OCT (C-scan(

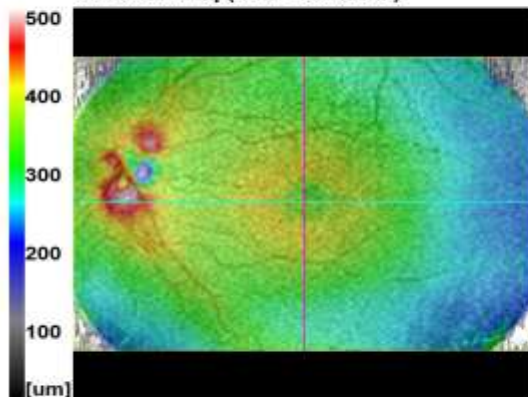
OCT Setting:MACULA MAP X-Y(12.0mm x 9.0mm[512 x 128])

Eye:L

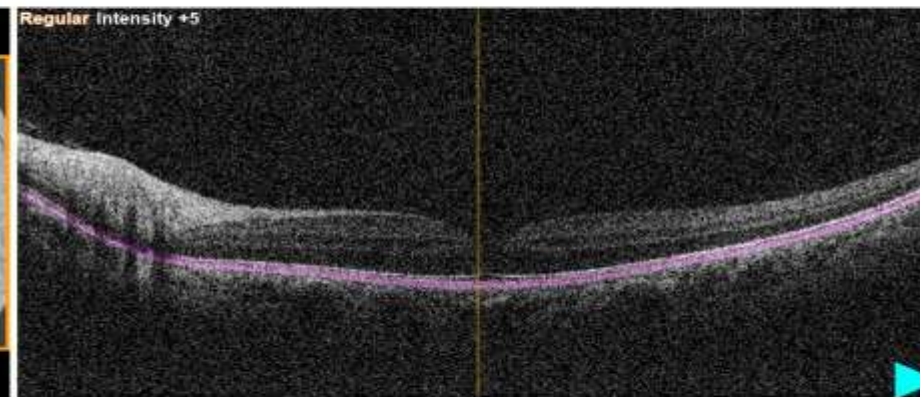
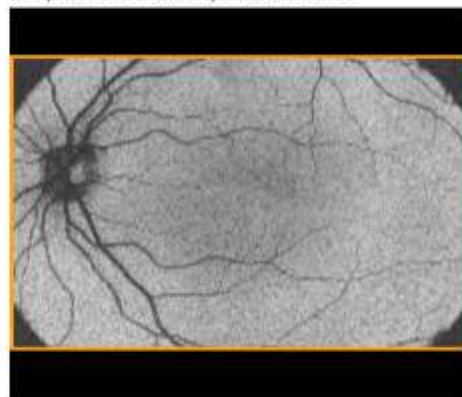
Retina Scan Duo

L	En face	S/N	Version(F/S)	Date	SQI	SSI	SLO	Focus[D]	Axial[mm]
		L 640678	10201/1.10.00	2/27/2018 20:36:27	---	8/10	---	-1.75	Gullestrand

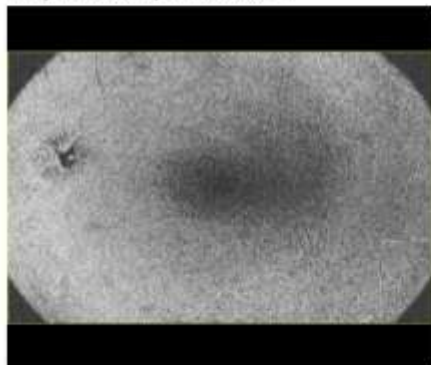
ThicknessMap(ILM - RPE/BM)



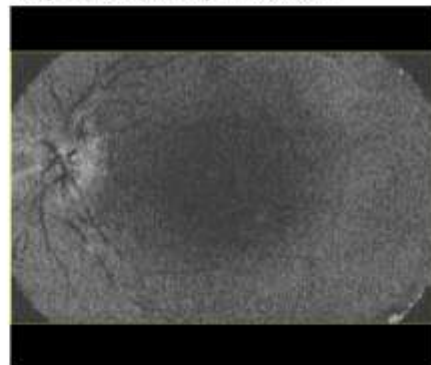
HIP, RPE/BM-42um, Thick:42um



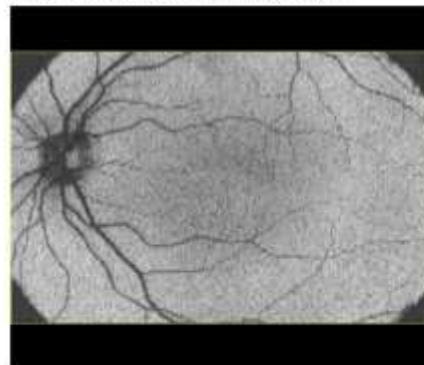
Vitreous interface
HIP, ILM+0um, Thick:42um



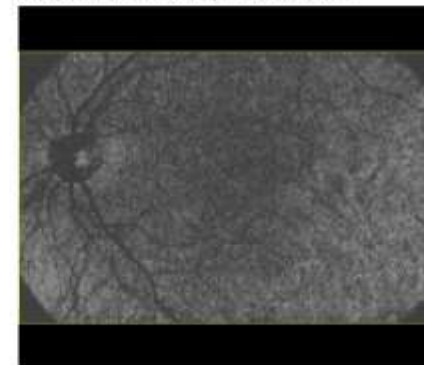
Inner retina
HIP, IPL/INL+21um, Thick:42um

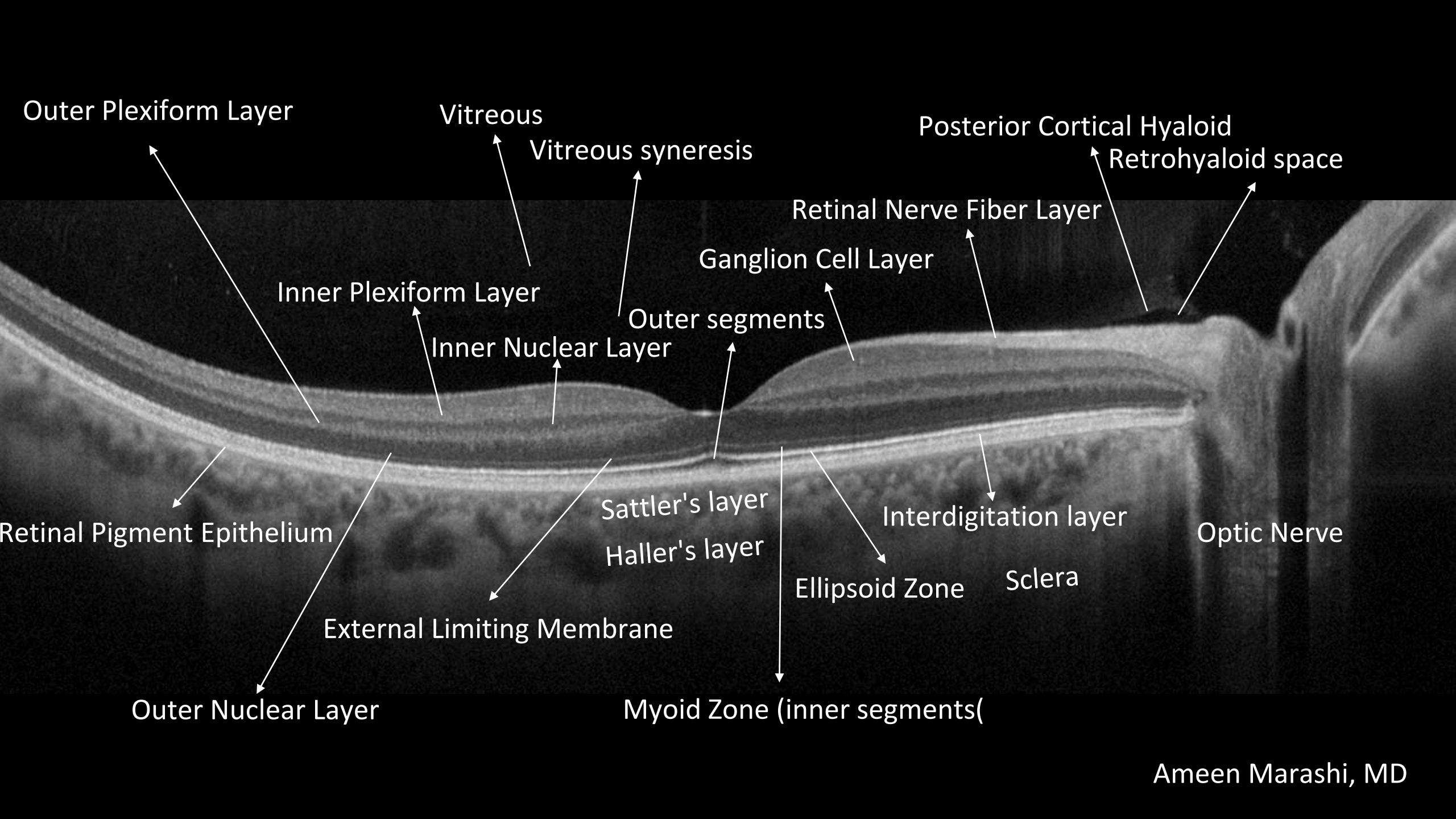


RPE
HIP, RPE/BM-42um, Thick:42um



Choroid
HIP, RPE/BM+0um, Thick:125um





Outer Plexiform Layer

Vitreous

Vitreous syneresis

Posterior Cortical Hyaloid

Retrohyaloid space

Inner Plexiform Layer

Retinal Nerve Fiber Layer

Ganglion Cell Layer

Inner Nuclear Layer

Outer segments

Retinal Pigment Epithelium

Sattler's layer

Interdigitation layer

Optic Nerve

Haller's layer

Ellipsoid Zone

Sclera

External Limiting Membrane

Outer Nuclear Layer

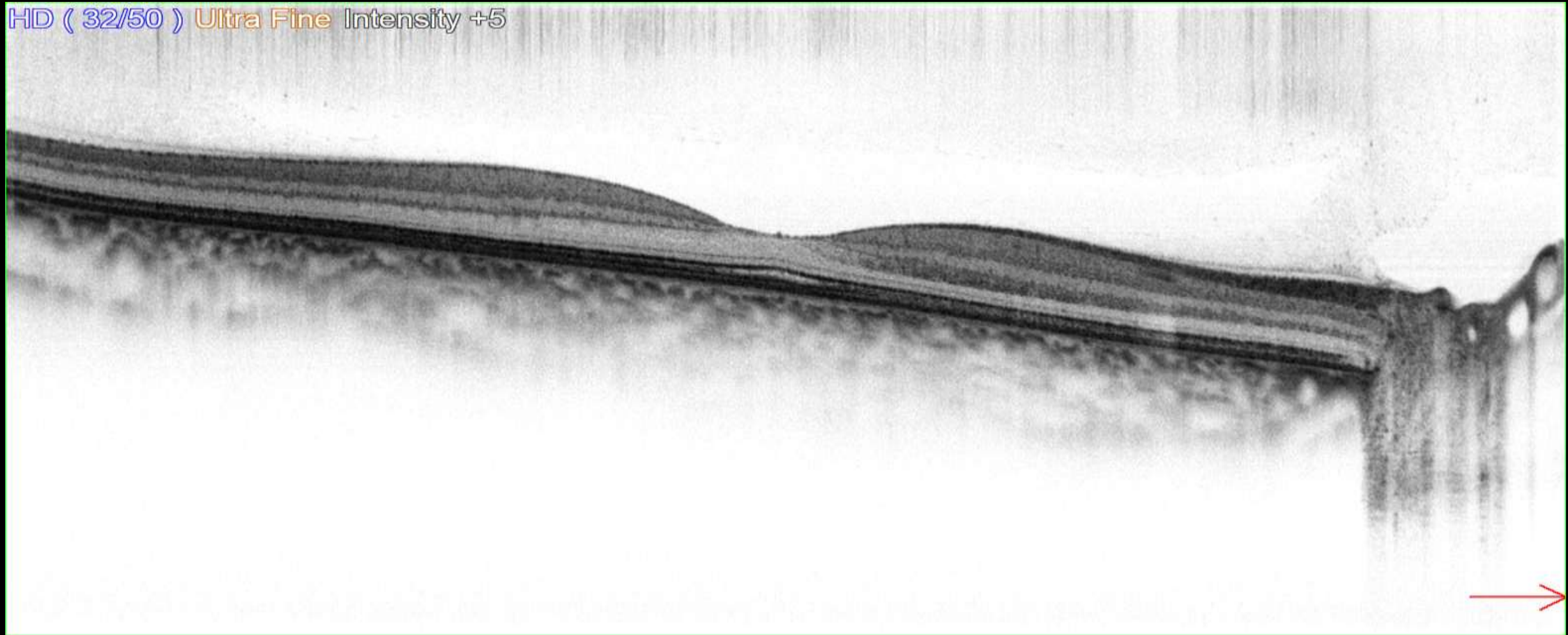
Myoid Zone (inner segments)

Ameen Marashi, MD

OCT- Macular Scan Types

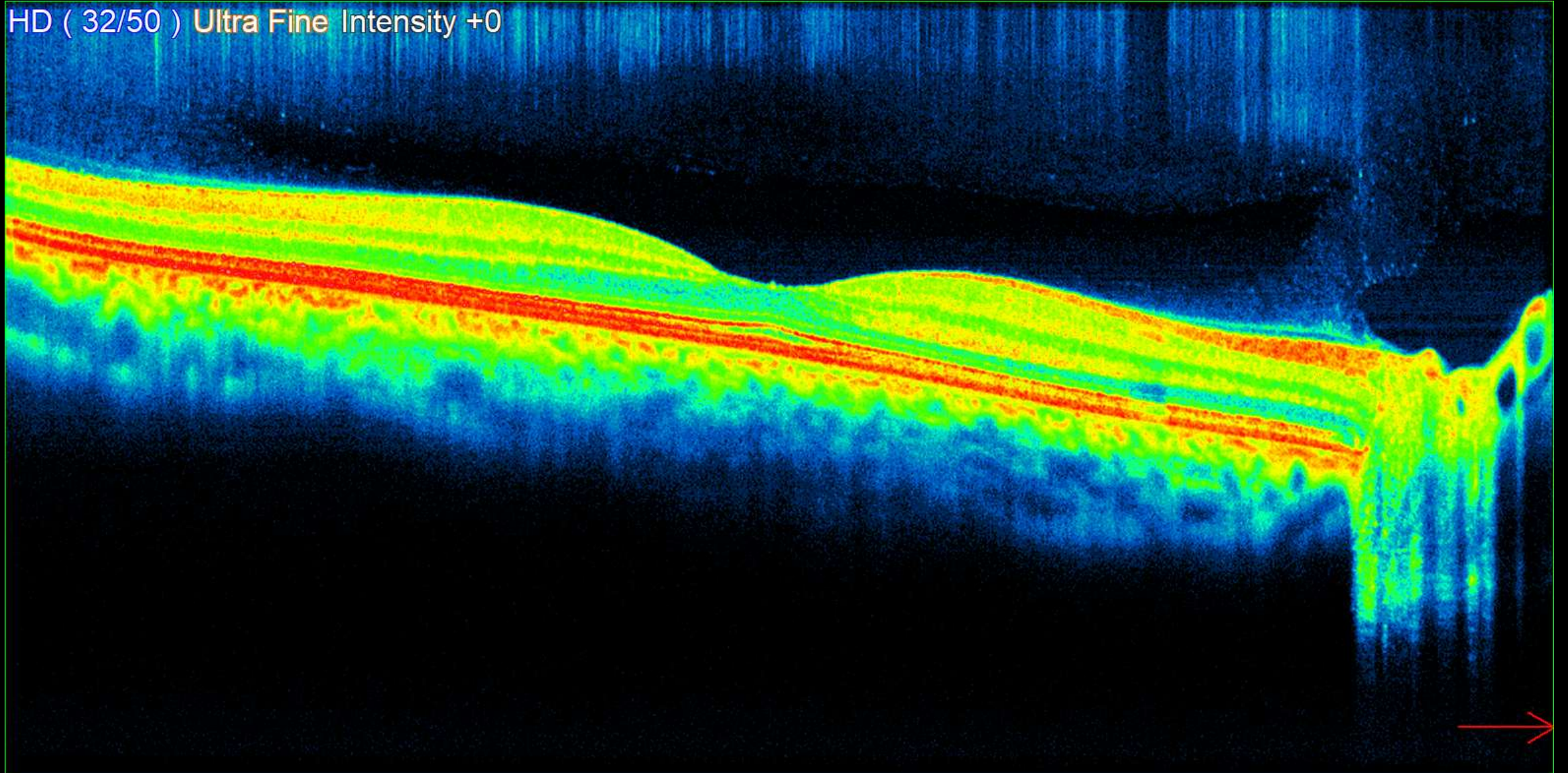
Normal Cross section- Negative

HD (32/50) Ultra Fine Intensity +5



OCT- Macular Scan Types

HD (32/50) Ultra Fine Intensity +0



OCT

- Vitreous
- Vitreous macular interface
- Retina
 - Retinal thickening, or cystic formation
 - Ellipsoid zone (IS/OS junctions)
 - SRF
 - RPE
- Choroid

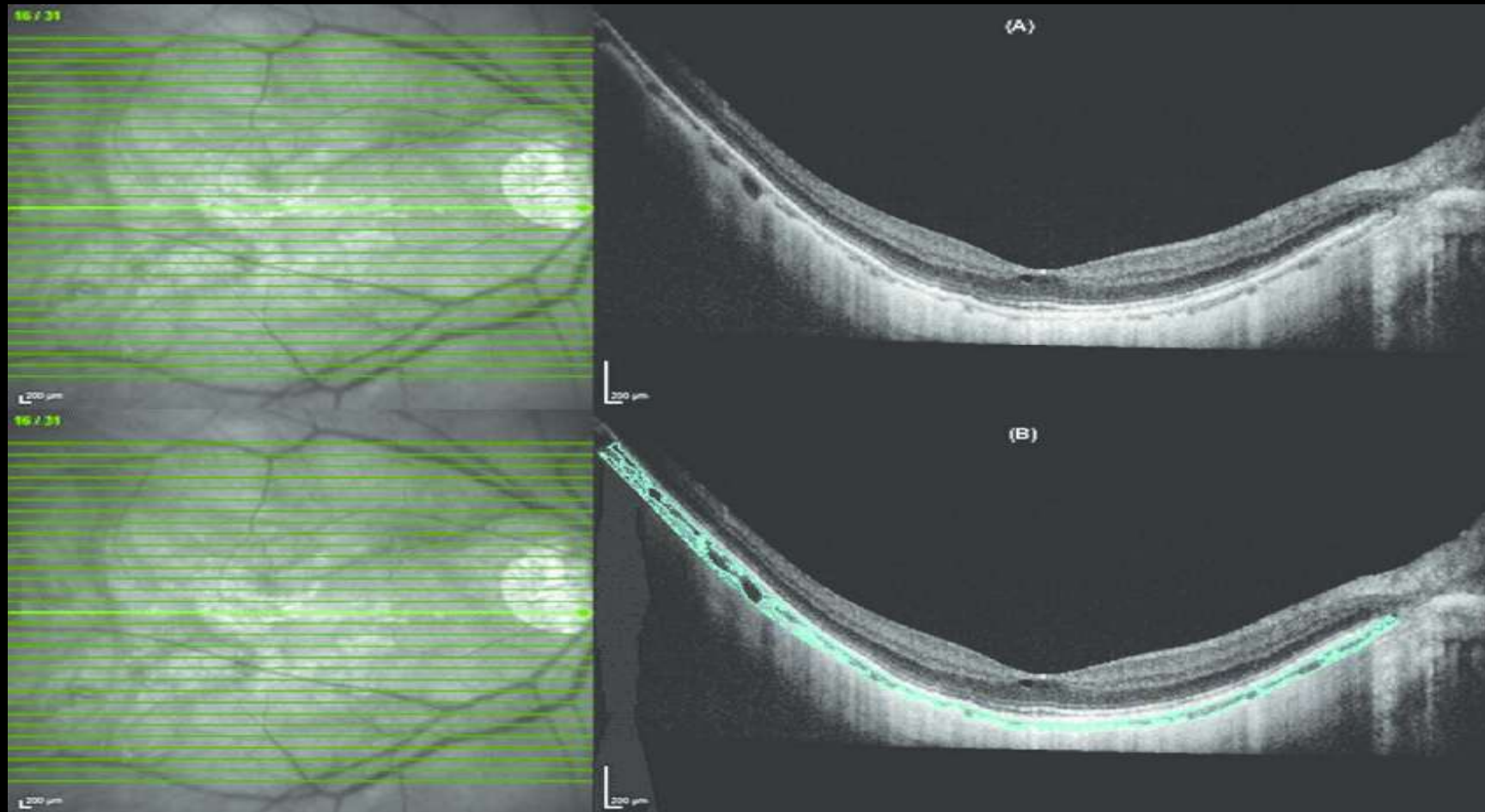
Pathological Findings in OCT

Common pathological findings

- Changes in retinal Contour**
- Retinal thickening**
- Retinal thinning**
- Retinal tissues structural changes**
- Retinal tissue reflectivity changes**

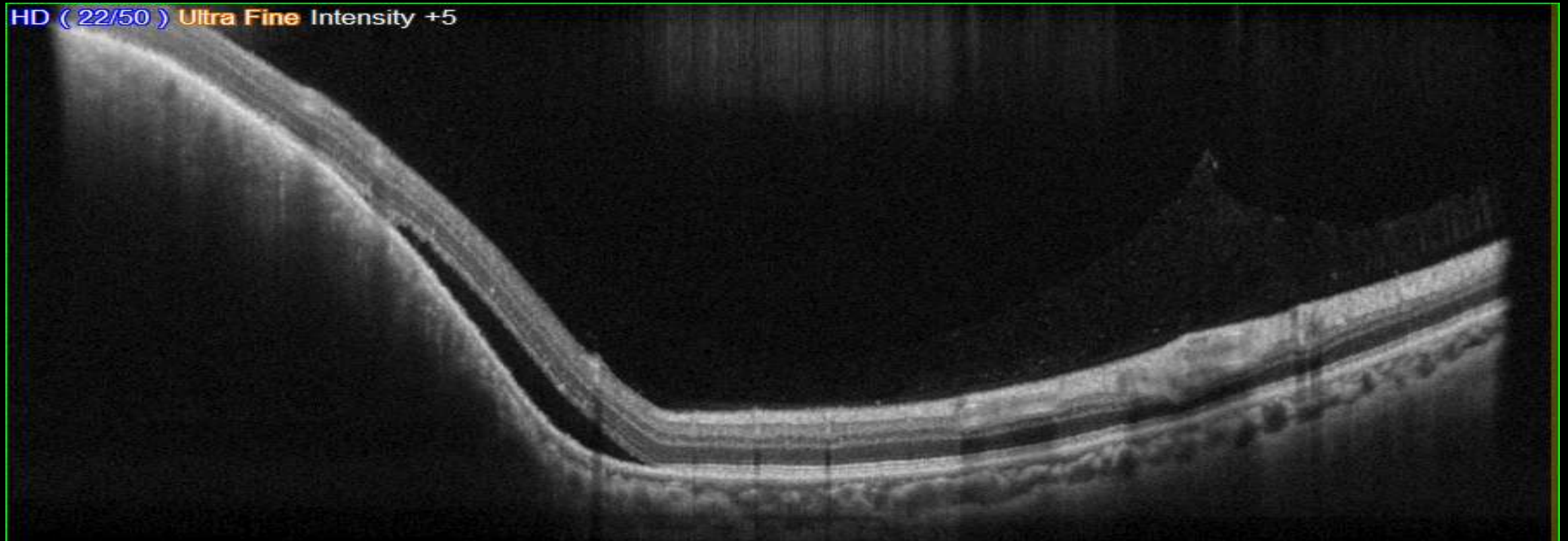
Common pathological findings

Changes in retinal contour



Common pathological findings

Changes in retinal contour

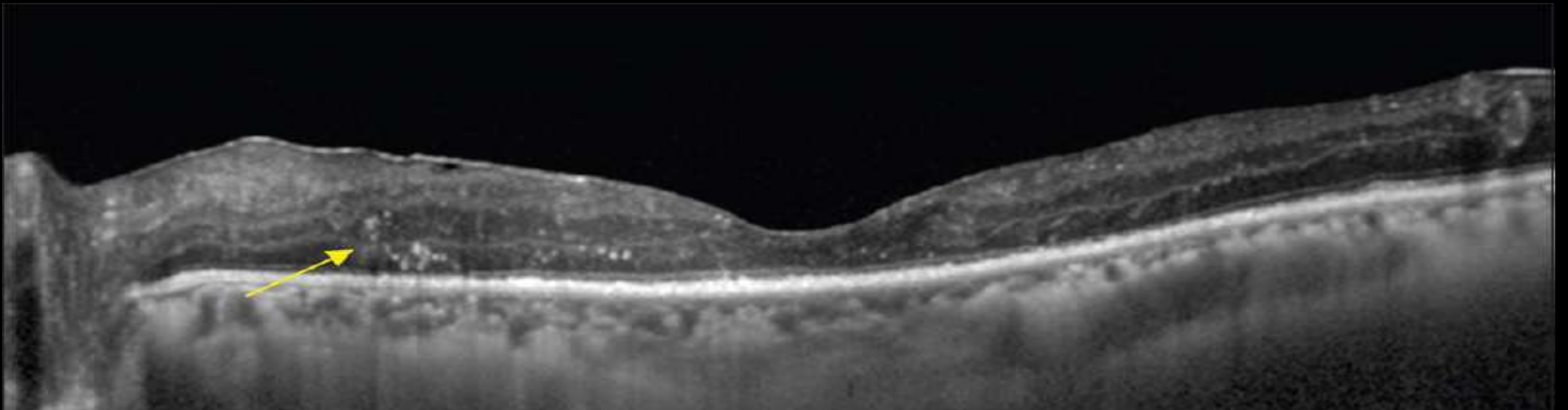


Retinal Thickening

- Retinal thickening**
- Cystic retinal changes**
 - **Tubular hypo-reflective spaces**
 - **Circular or Oval Hypo-reflective and non empty spaces**
- Retinal elevation**

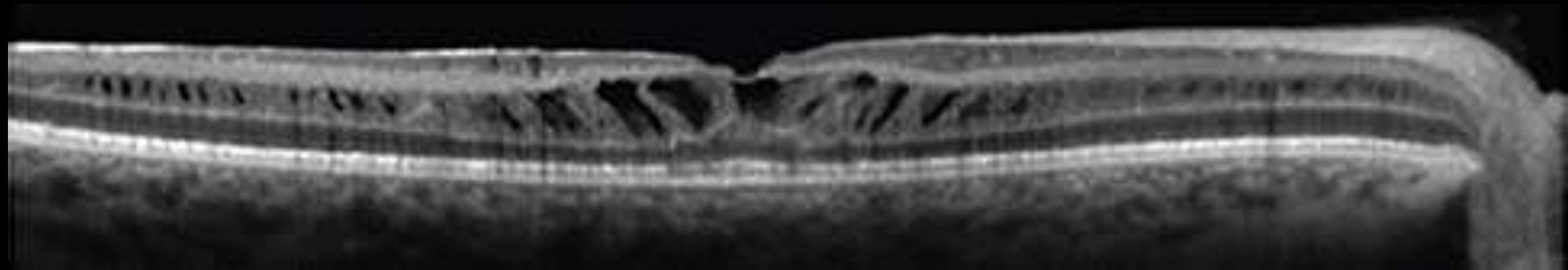
Retinal Thickening

Retinal thickening



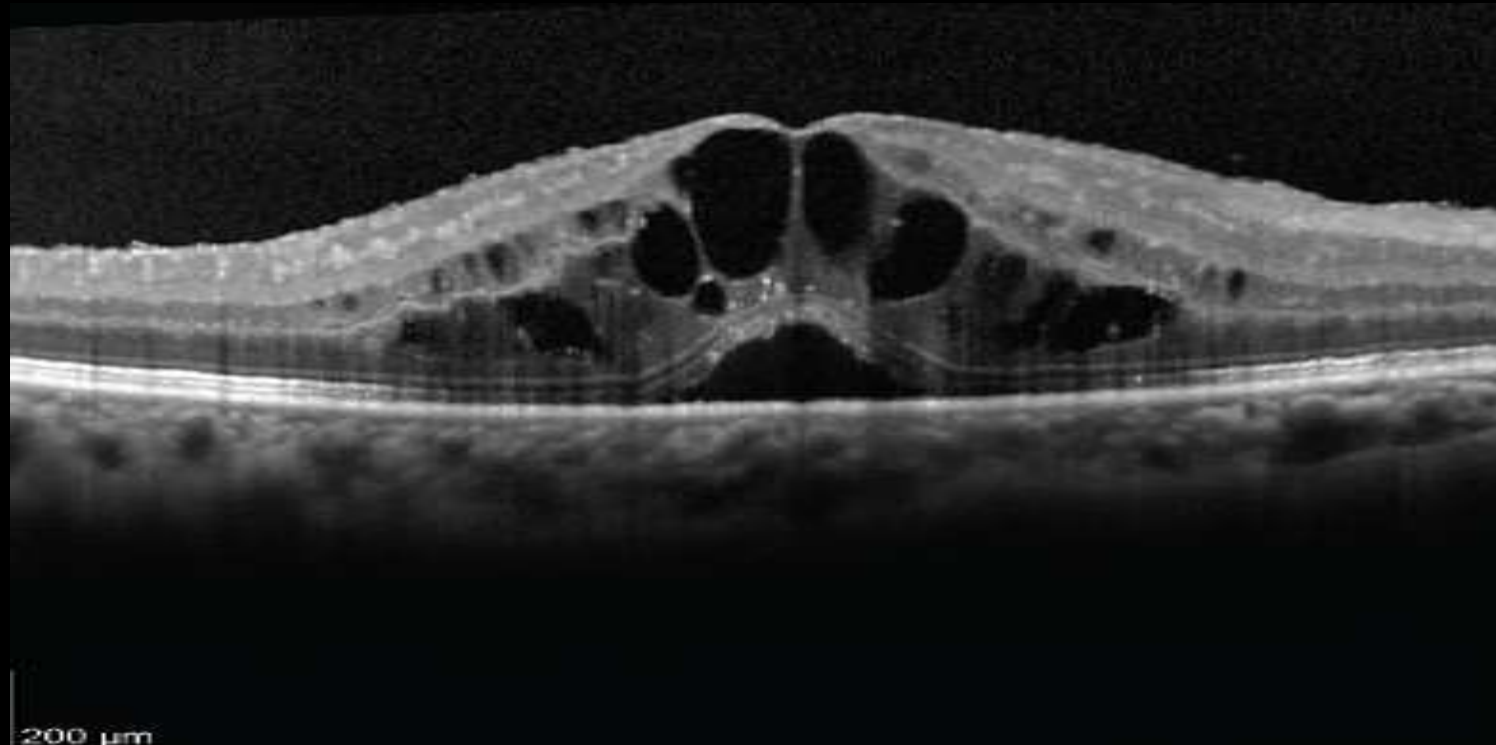
Retinal Thickening

Tubular hypo-reflective spaces (Retinoschisis)



Retinal Thickening

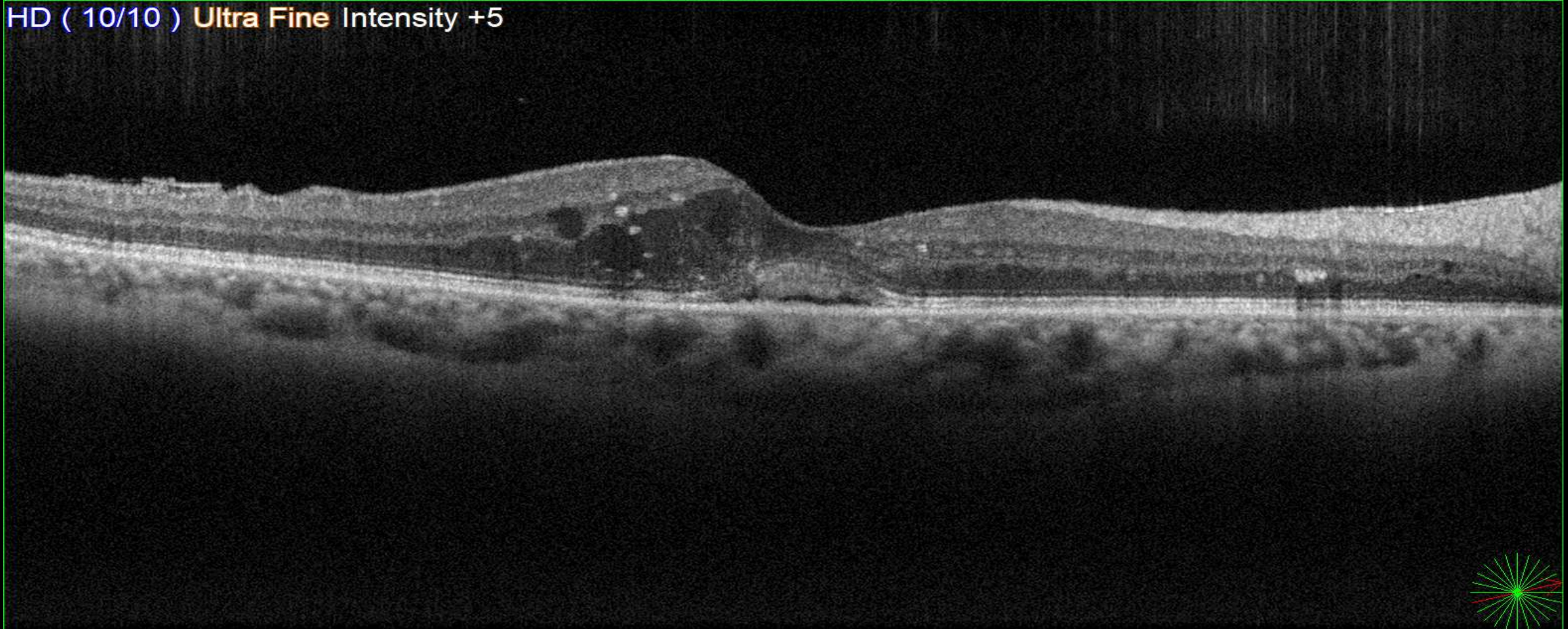
Oval or Circular hypo-reflective spaces



Retinal Thickening

Oval or Circular non empty spaces

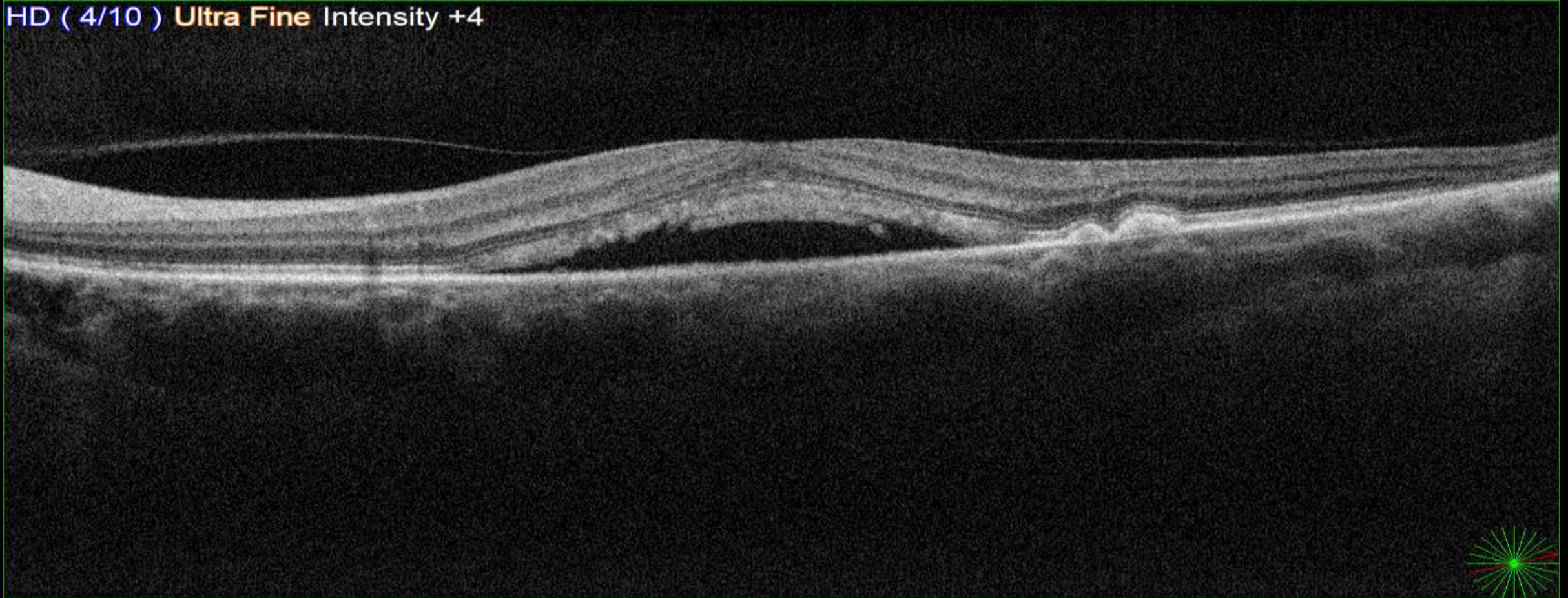
HD (10/10) Ultra Fine Intensity +5



Retinal Thickening

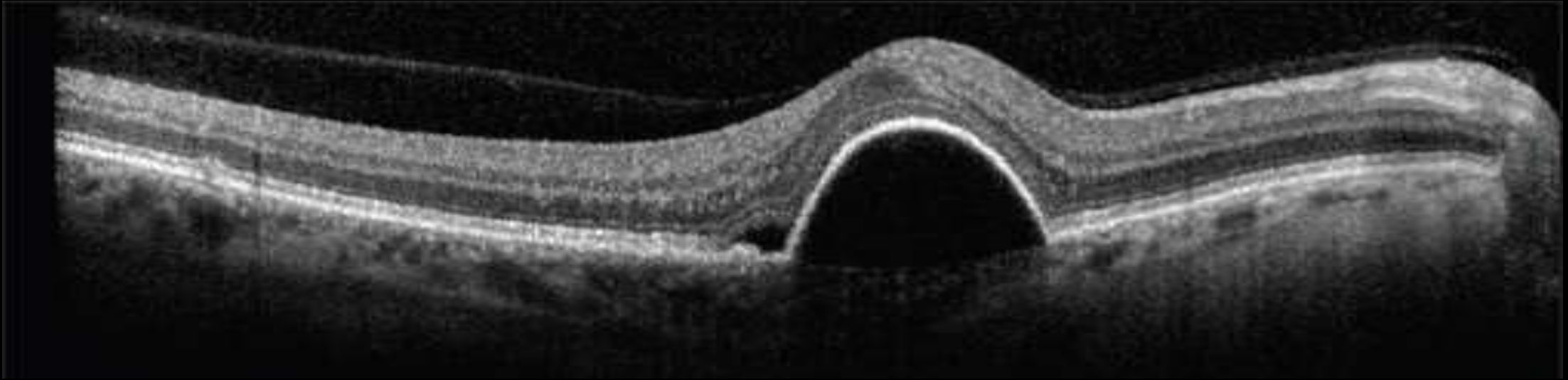
Retinal elevation (Sub retinal Fluid(

HD (4/10) Ultra Fine Intensity +4



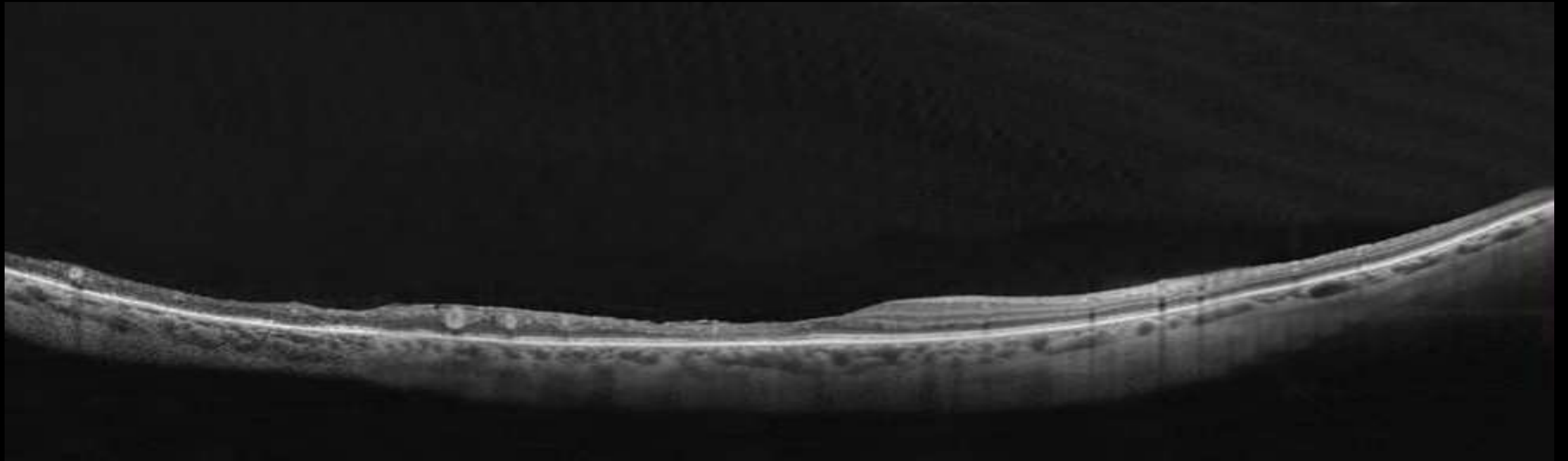
Retinal Thickening

Retinal elevation (PED)



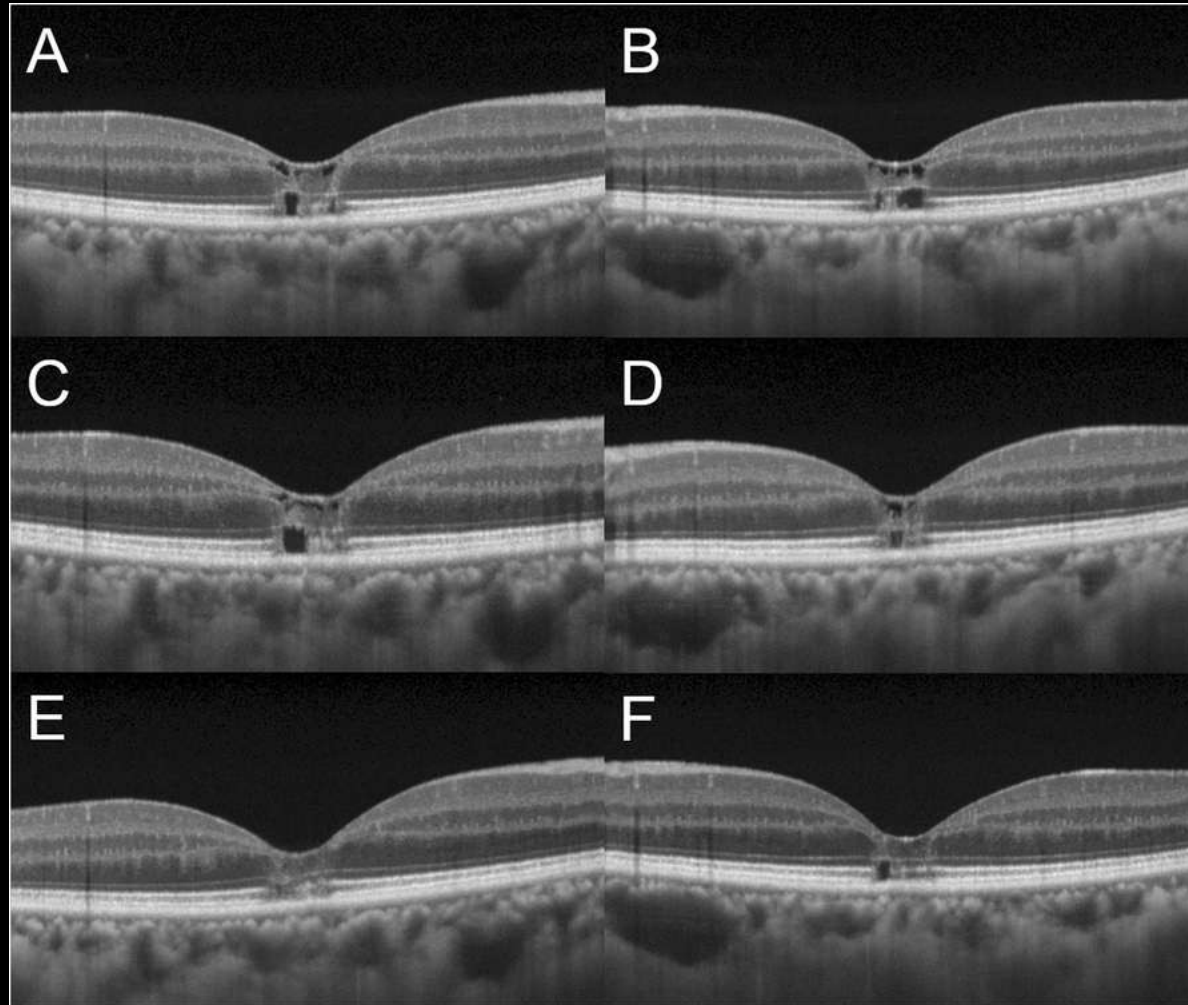
Retinal Thinning

Ischemic changes



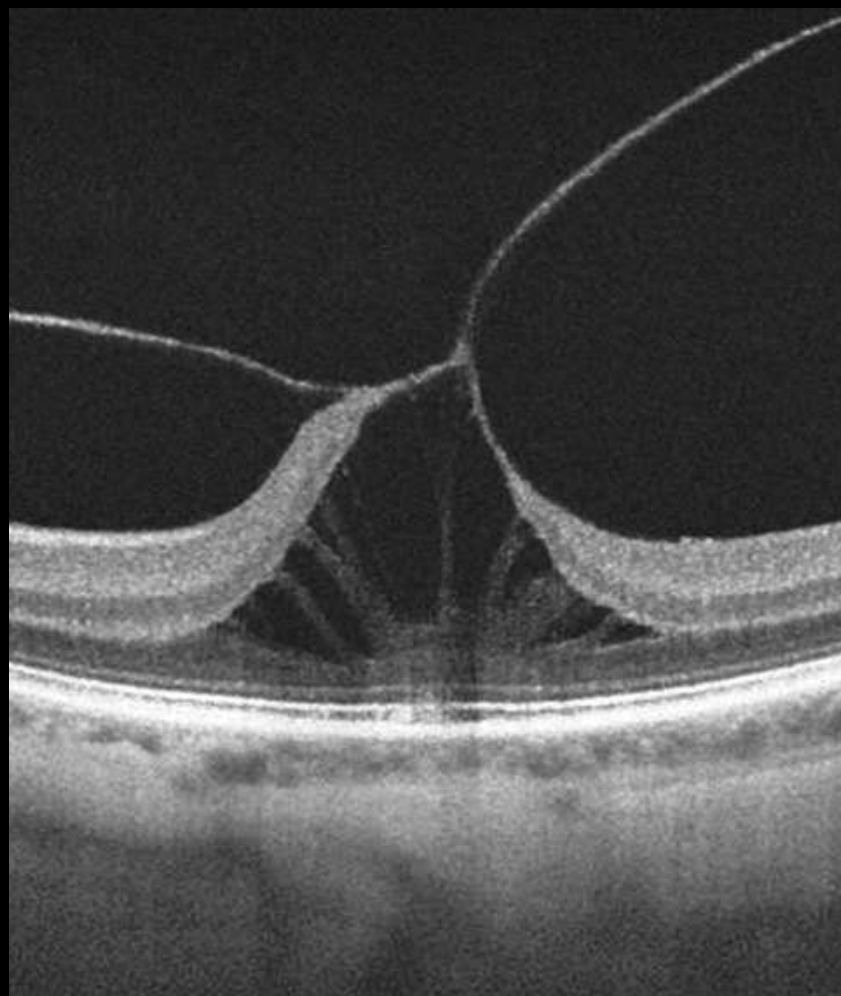
Retinal Thinning

Intraretinal cavitation



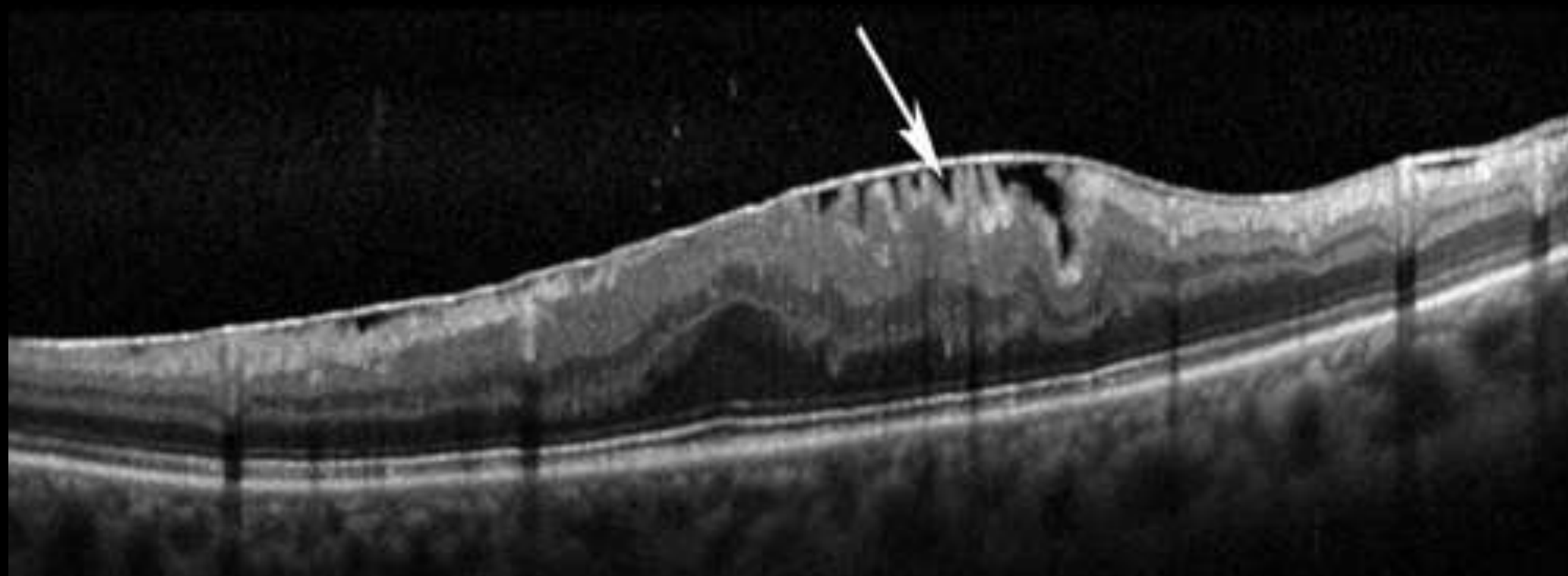
Retinal tissues structural changes

Vitreo-Macular abnormalities (VMT)



Retinal tissues structural changes

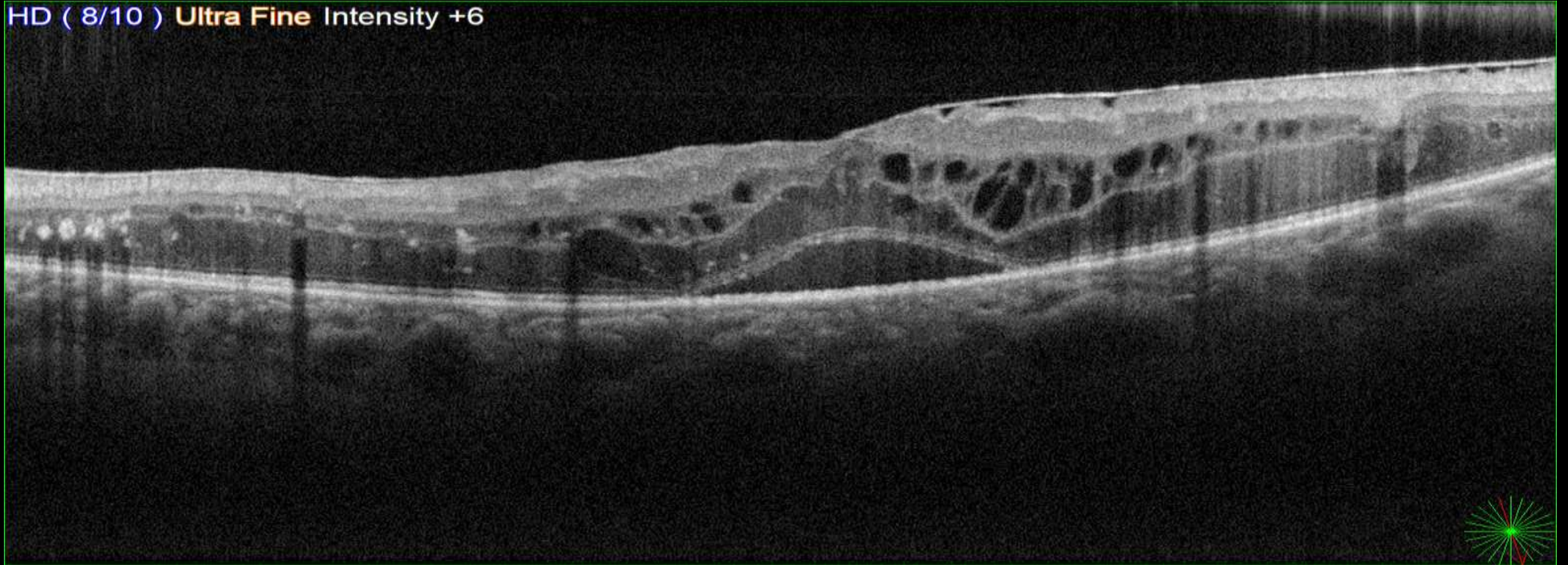
Vitreo-Macular abnormalities (ERM (



Retinal tissues structural changes

Disorganization of inner retinal layer

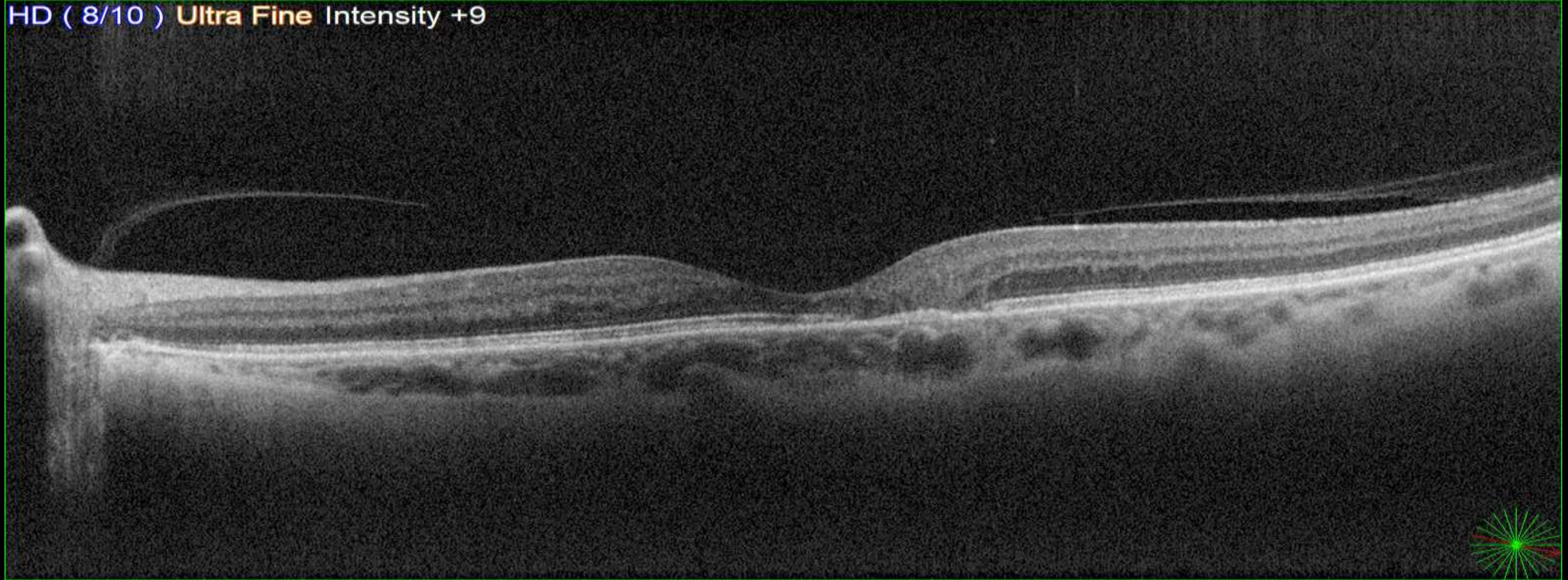
HD (8/10) Ultra Fine Intensity +6



Retinal tissues structural changes

Disruption of ellipsoid zone

HD (8/10) Ultra Fine Intensity +9



Retinal tissues structural changes

Drusen

