

The background is a dark blue gradient with a pattern of white circular lines and arrows, some of which are part of a larger scale. The scale is a semi-circular arc with tick marks and numbers ranging from 140 to 260. The numbers are: 140, 150, 160, 170, 180, 190, 200, 210, 220, 230, 240, 250, 260. The text is centered in the middle of the image.

LENS RELATED GLAUCOMA

SALADIN MUGHARBEL MD

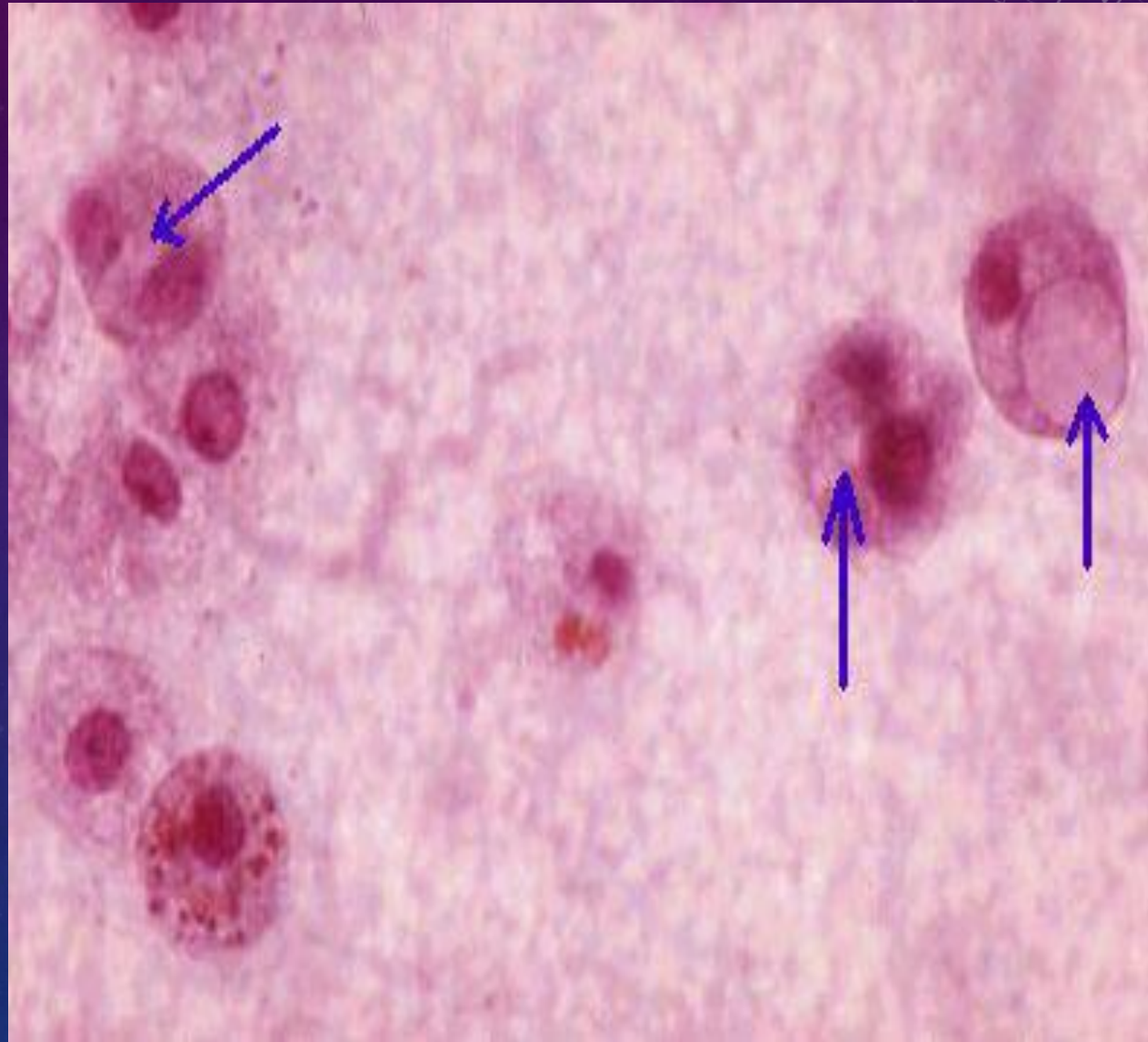
LENS RELATED GLAUCOMA

- Phacolytic glaucoma
- Lens particle glaucoma
- Phacoanaphylaxis glaucoma
- Phacomorphic glaucoma
- IOL related glaucoma

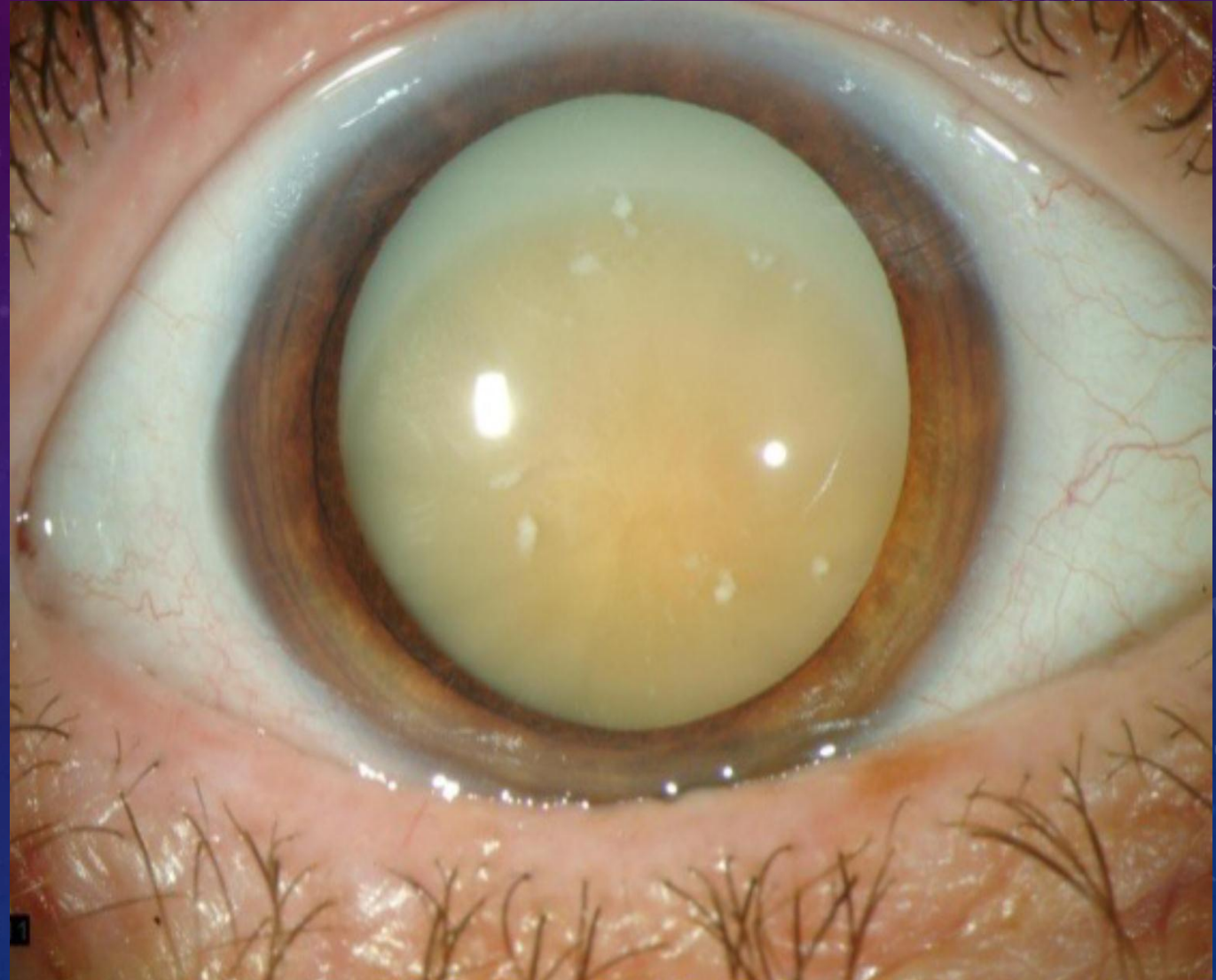
PHACOLYTIC

What does Phacolytic ,melanocytic and hemolytic glaucoma have in common ?

MACROPHAGES (Phagocytosis)



PHACOLYTIC



PATHOGENESIS OF PHACOLYTIC GLAUCOMA

- Leakage of lens proteins, more high-molecular weight proteins
- Macrophages to engulf protein
- **Obstruction of the TM**

PRESENTATION OF PHACOLYTIC GLAUCOMA

- Abrupt onset of pain ,redness,worse vision
- Usually elderly patient with long standing cataract

EXAM

High IOP

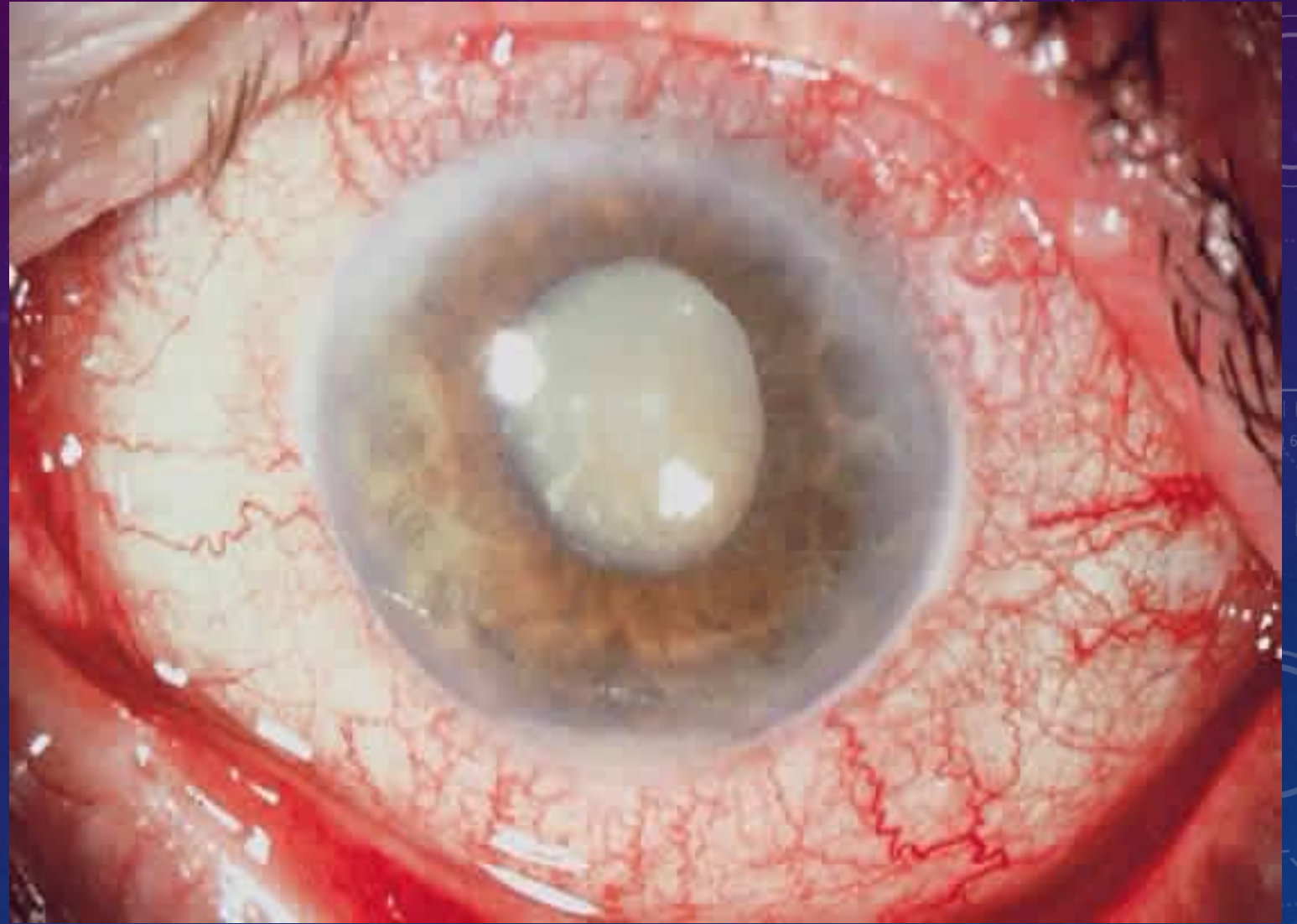
Corneal edema

Mature cataract

Open angle

No KPs

Possible hypopyon



TREATMENT FOR PHACOLYTIC GLAUCOMA

- Topical steroid
- Medication for glaucoma
- **Prompt cataract surgery**

SURGERY FOR PHACOLYTIC GLAUCOMA

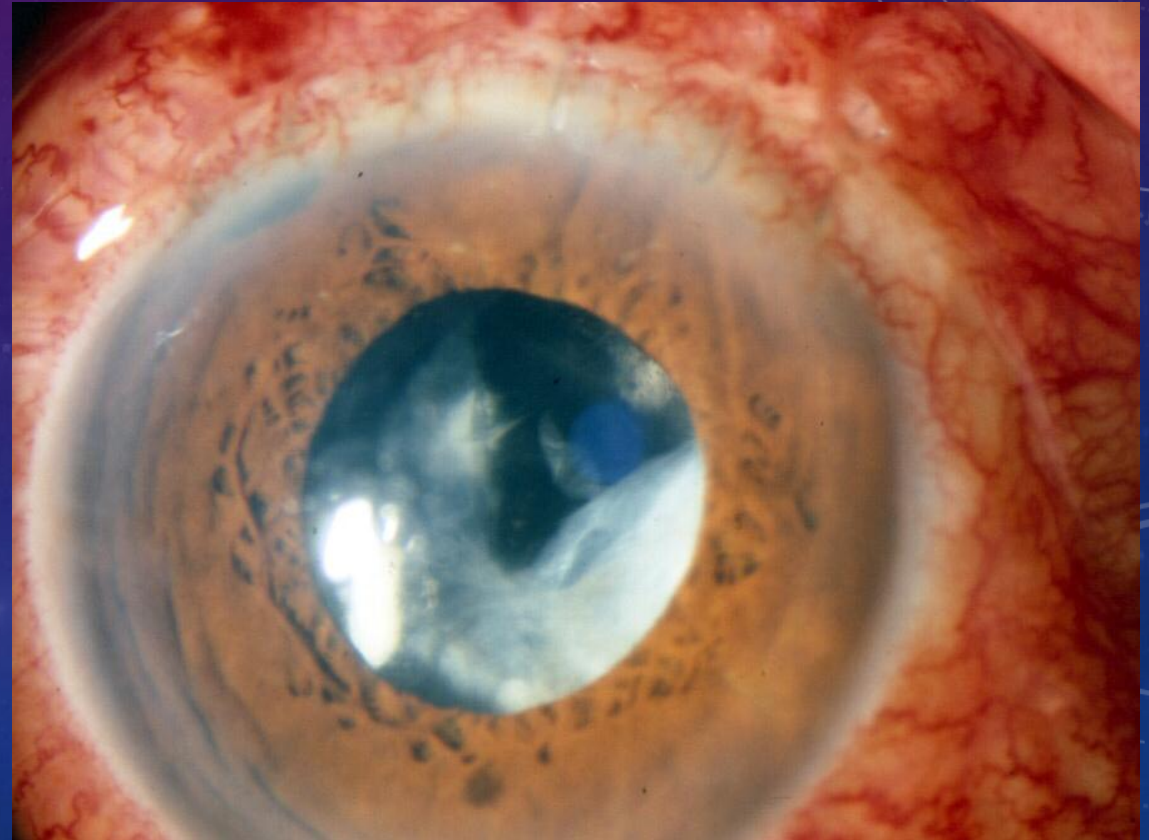
- Cataract extraction ?
- Combined surgery ??

LENS PARTICLE GLAUCOMA

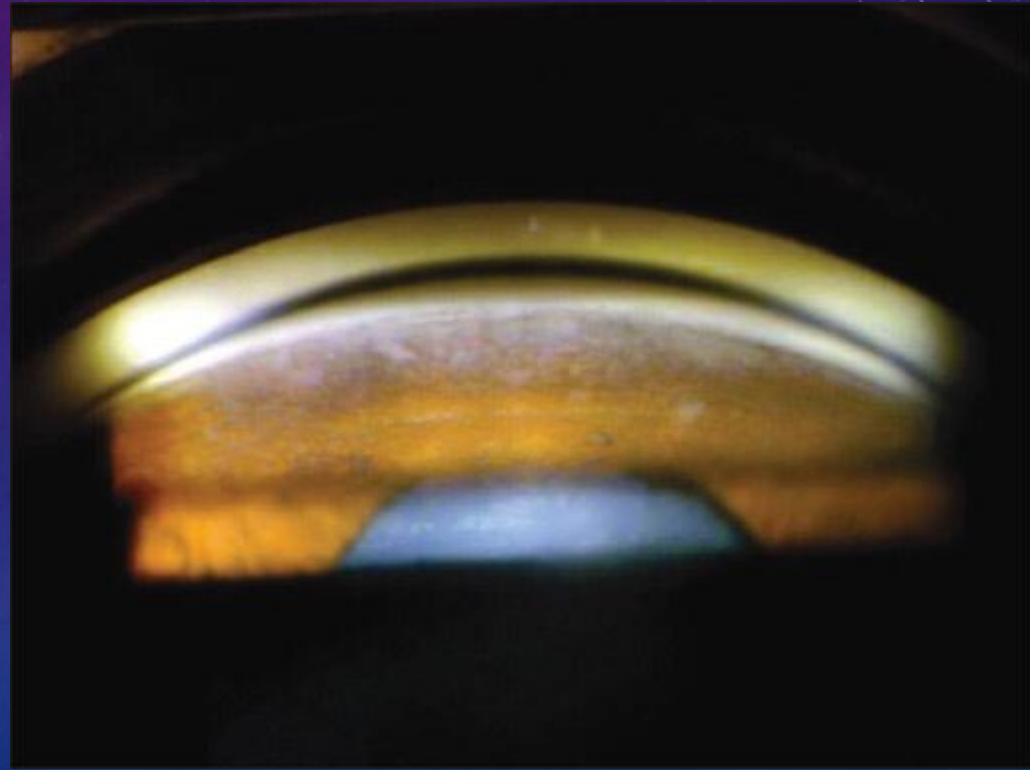
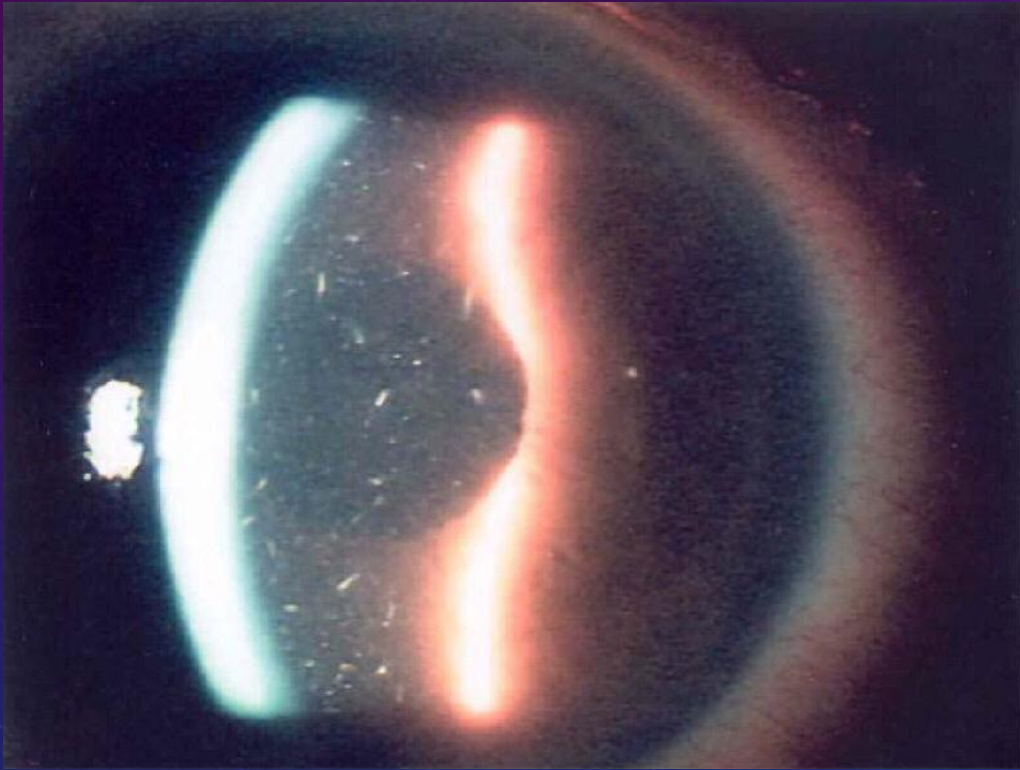
- Penetration of the lens /trauma
- YAG cap ?
- Post -op

LENS PARTICLE GLAUCOMA -PRESENTATION

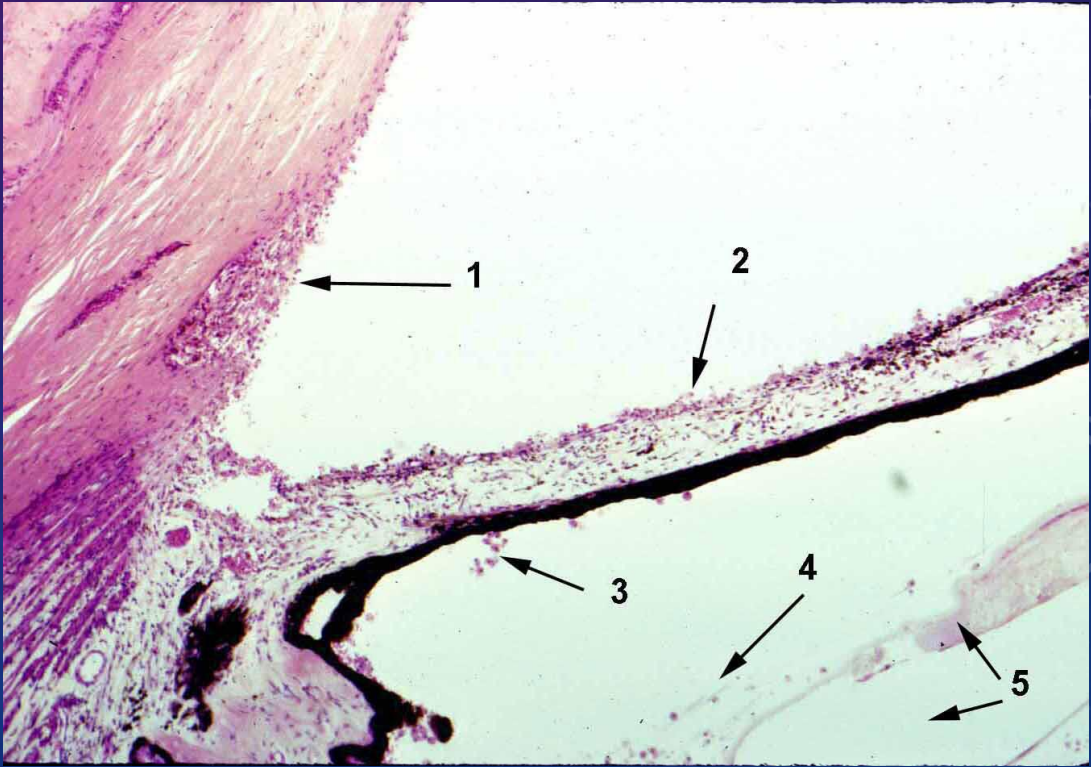
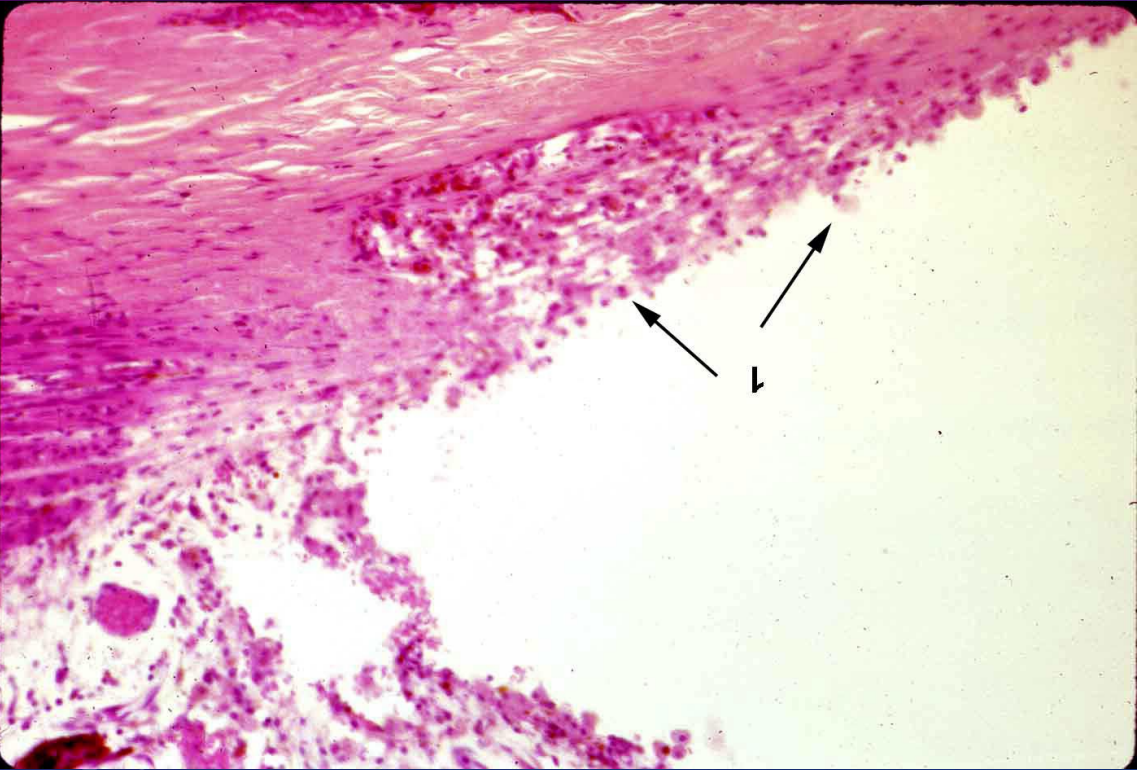- asymptomatic ?
- Sometimes pain , redness,blurry vision and nausea
- Hx of cataract surgery or trauma.. Remote .?
- Dropped lens fragments



LENS PARTICLE GLAUCOMA – EXAMINATION



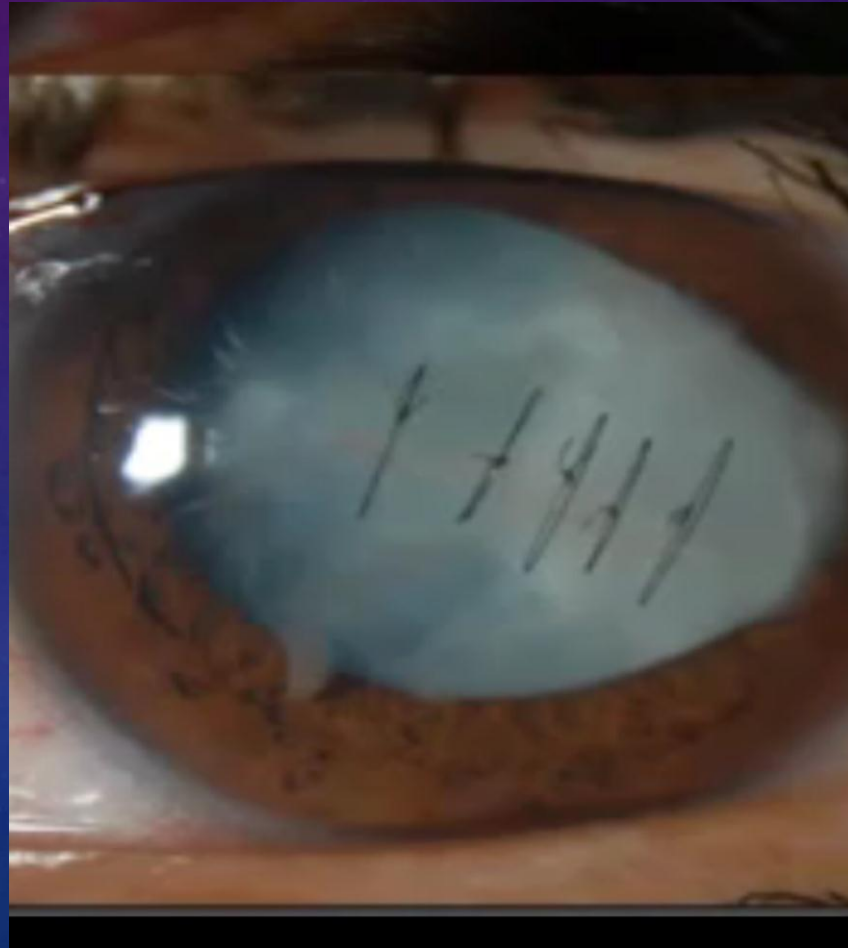LENS PARTICLE GLAUCOMA -PATHOLOGY



- Onset of lens particle glaucoma ?

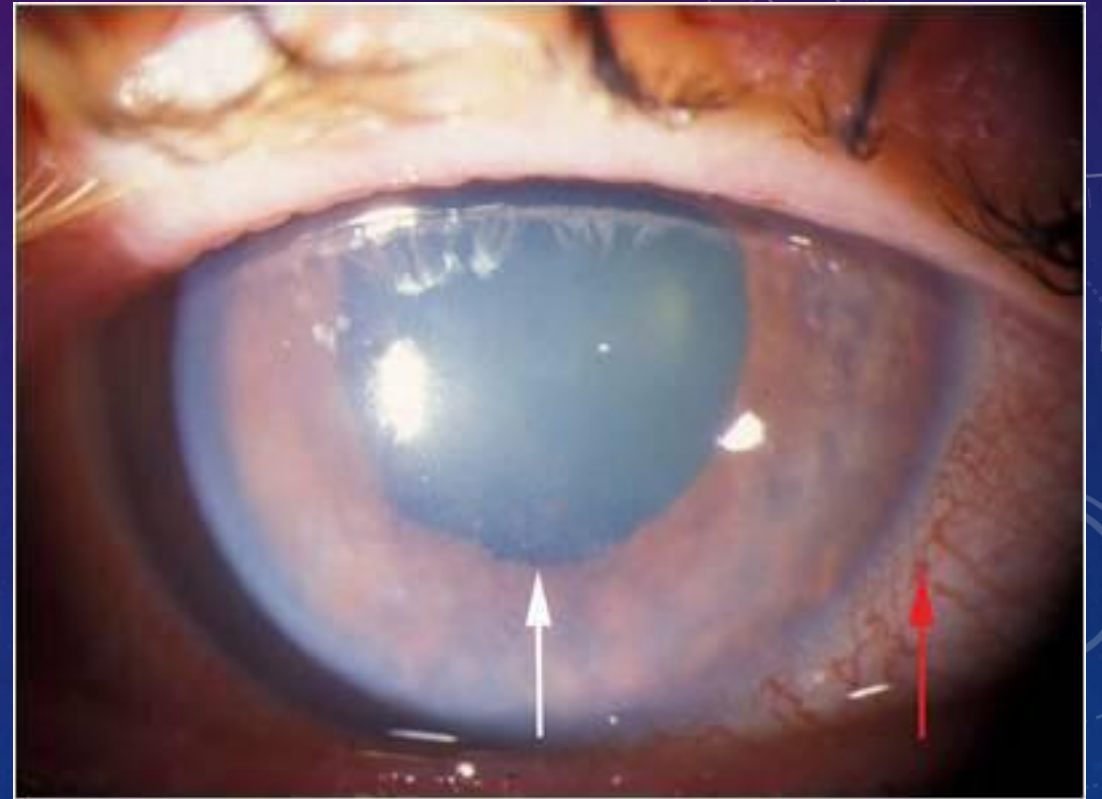LENS PARTICLE GLAUCOMA TREATMENT

- AC wash out
- Trab
- Vit ant , Post



PHACOANAPHYLAXIS GLAUCOMA

- Very rare and serious
- Zonal granulomatous Rxn
- KP often
- Lost tolerance to lens proteins

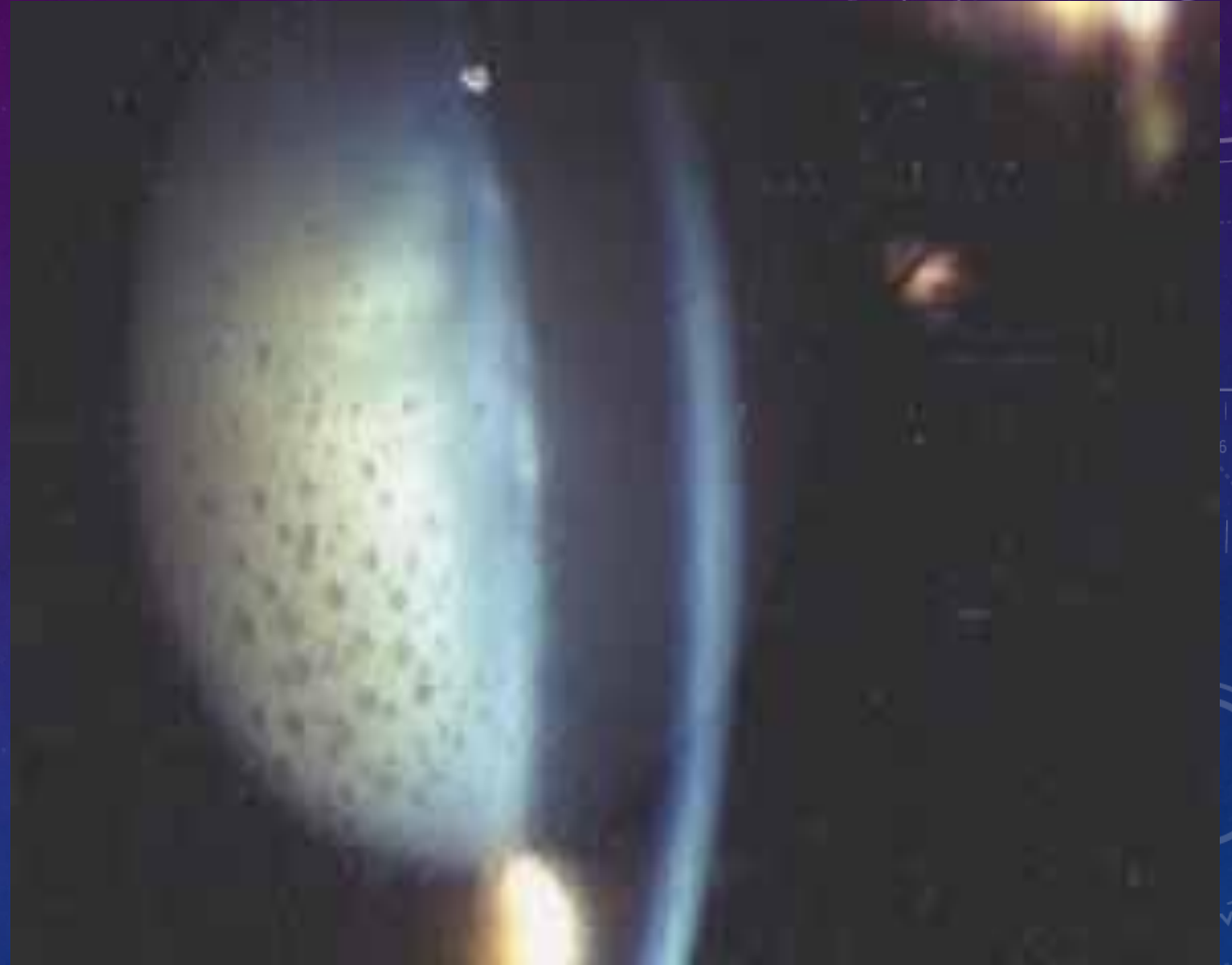

KP

Inflammatory cells

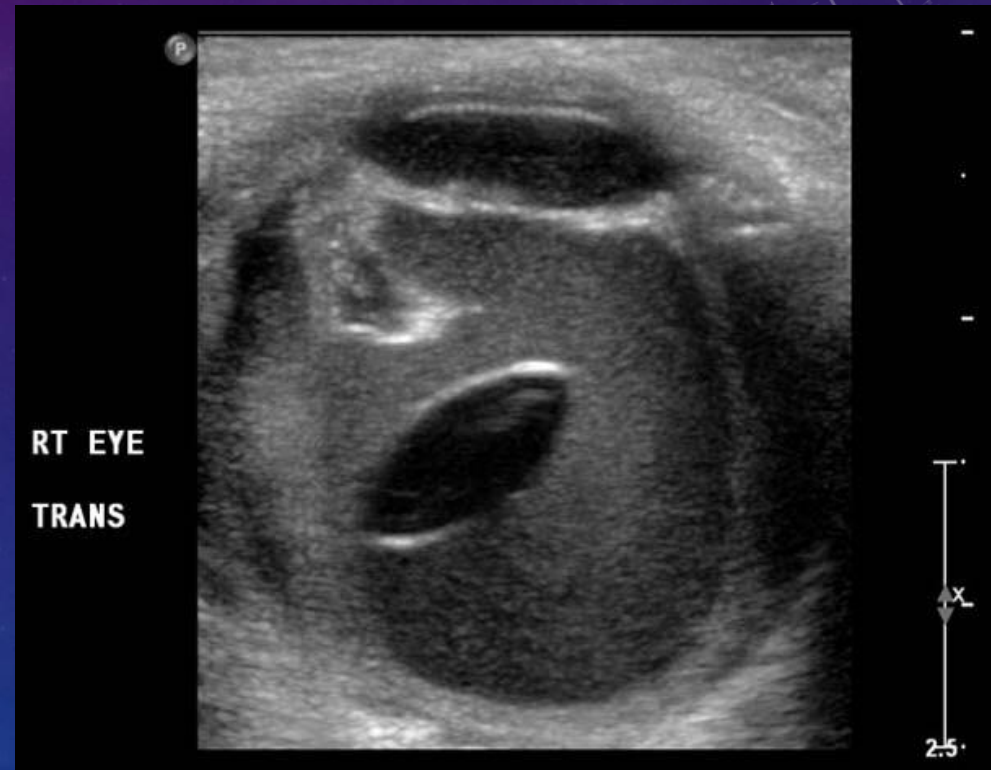
Hypersensitivity

Rxn



PHACOANAPHYLAXIS PRESENTATION

- A common cause is dropped nucleus
- Often require PPV
- Resembles SO , endophthalmitis , toxic uveitis

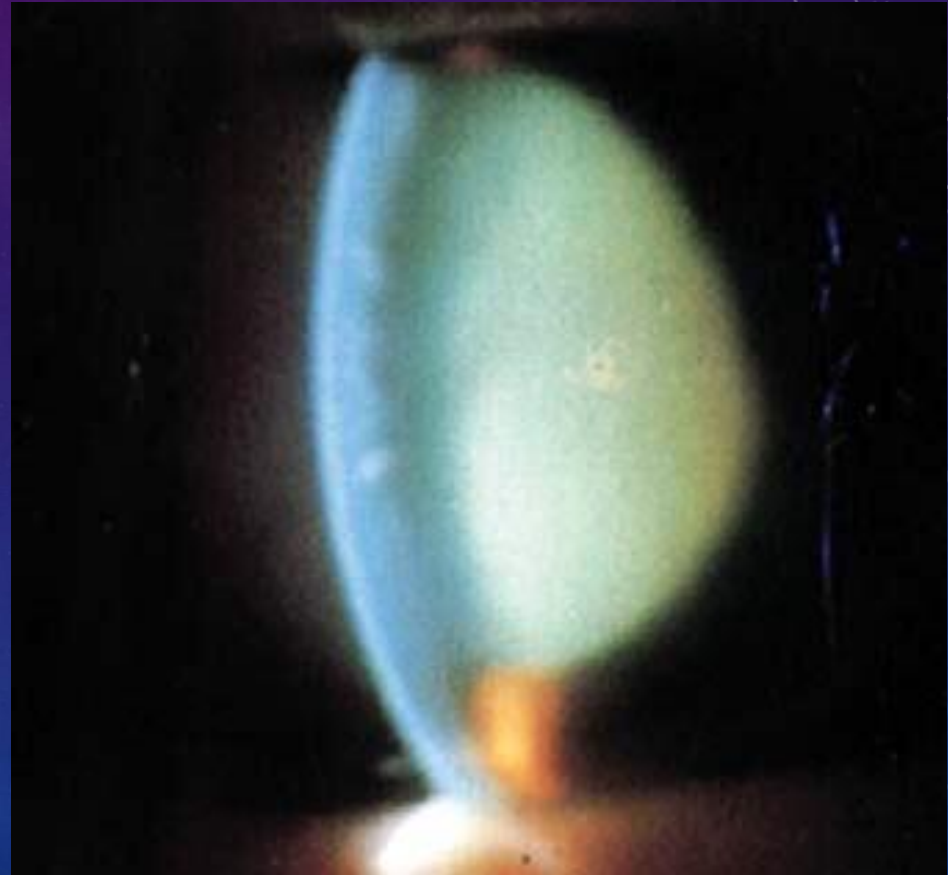


PHACOMORPHIC GLAUCOMA

- Patients present with acute angle closure picture as mature cataract suddenly becomes intumescent
- **Eyes not prone to angle closure at baseline**

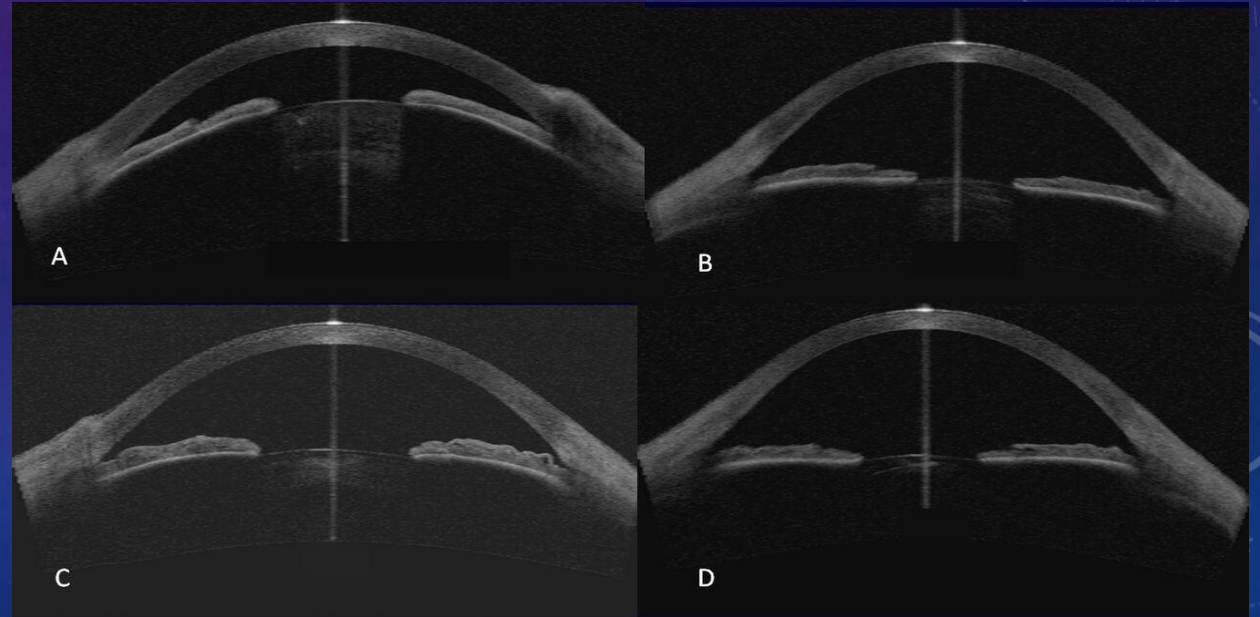
PHACOMORPHIC GLAUCOMA

- Angle closure picture



PHACOMORPHIC GLAUCOMA

- Eyes not prone to angle closure at base line



PHACOMORPHIC GLAUCOMA

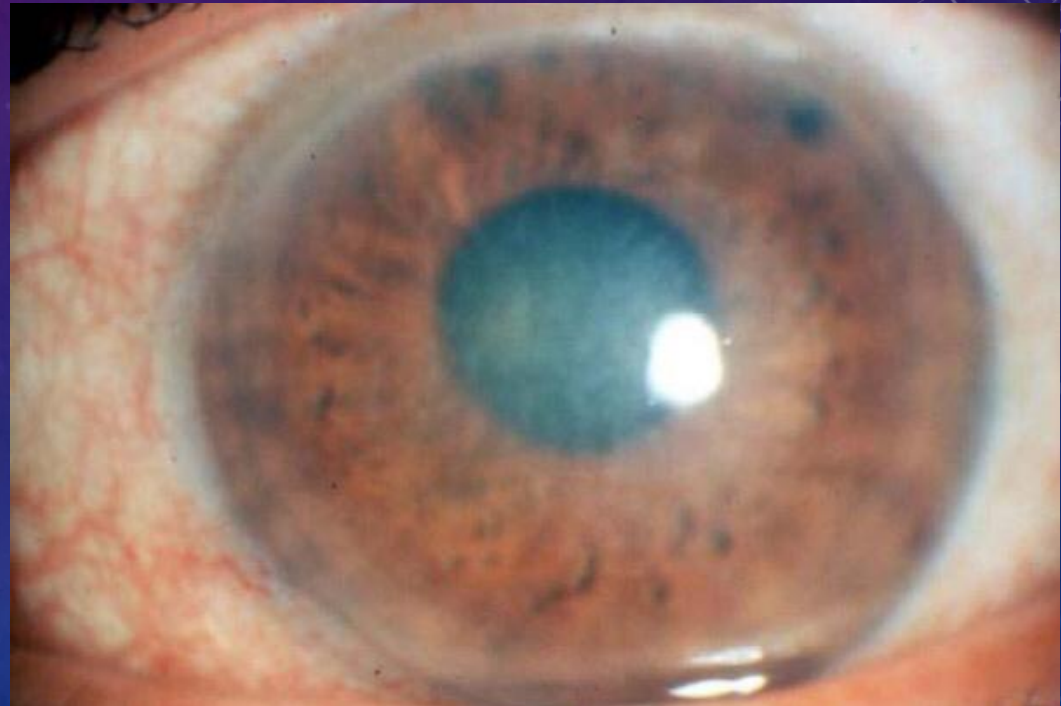- Lower IOP as possible
- Treat pupillary block first with LPI
- Cataract extraction (**precautions**)

CREEPING OR CHRONIC ANGLE CLOSURE GLAUCOMA

- Hyperopic patients
- Progressive shallowing of the AC due to increasing A-P lens diameter
- Not always easy to distinguish from phacomorphic

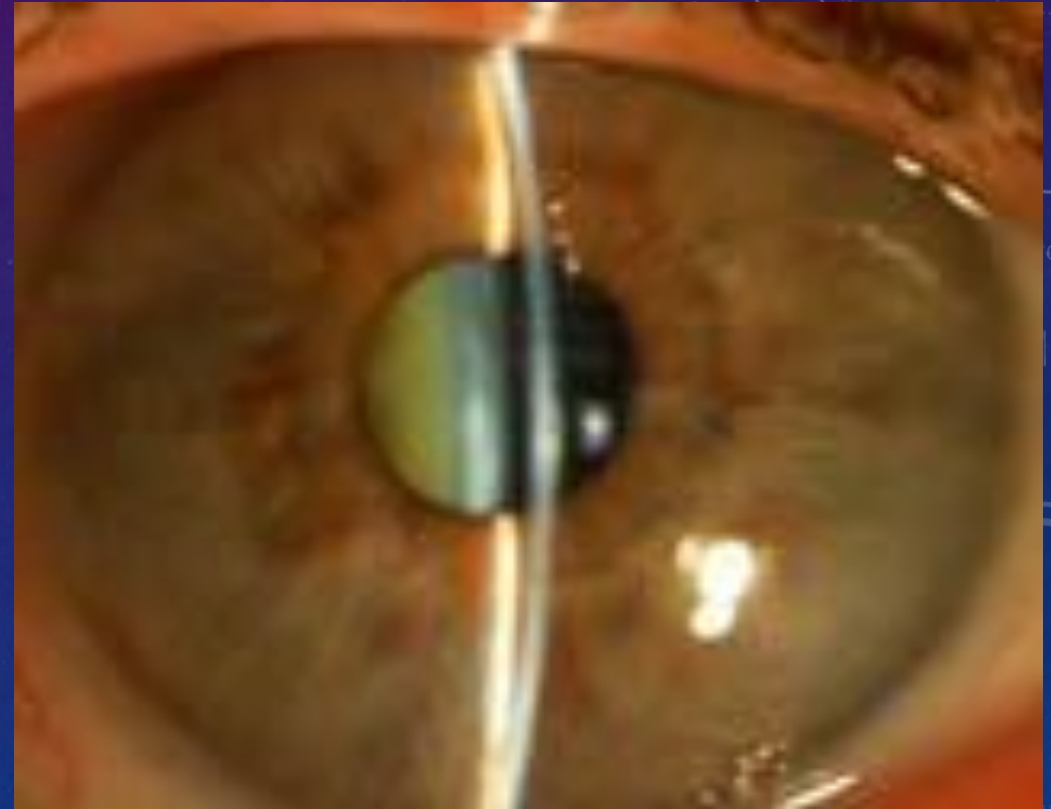CHRONIC ANGLE CLOSURE

- Monitor angle as cataract develop
- Avoid PAS and CACG by timely cataract surgery

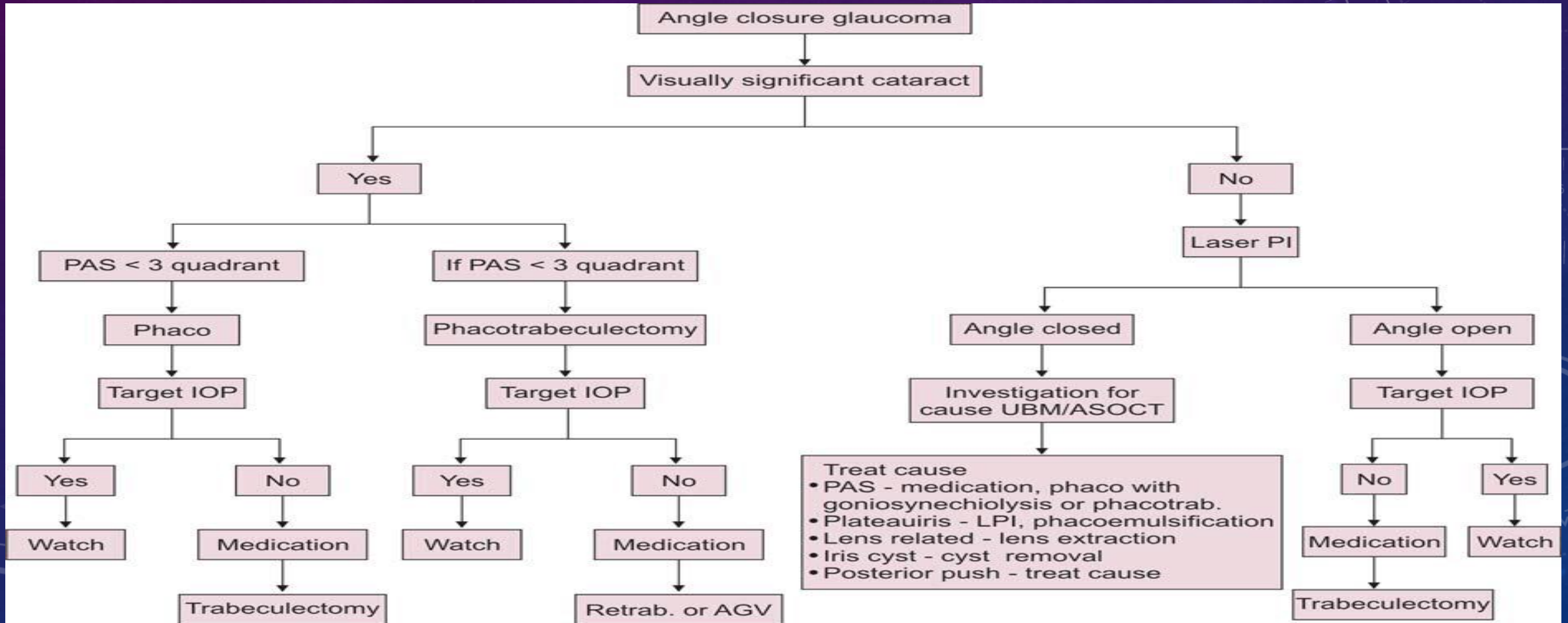


CHRONIC ANGLE CLOSURE GLAUCOMA

- **Remember:**
- Normal ACD 2.8mm
- Endothelial cell count ?
- Aqueous misdirection ?

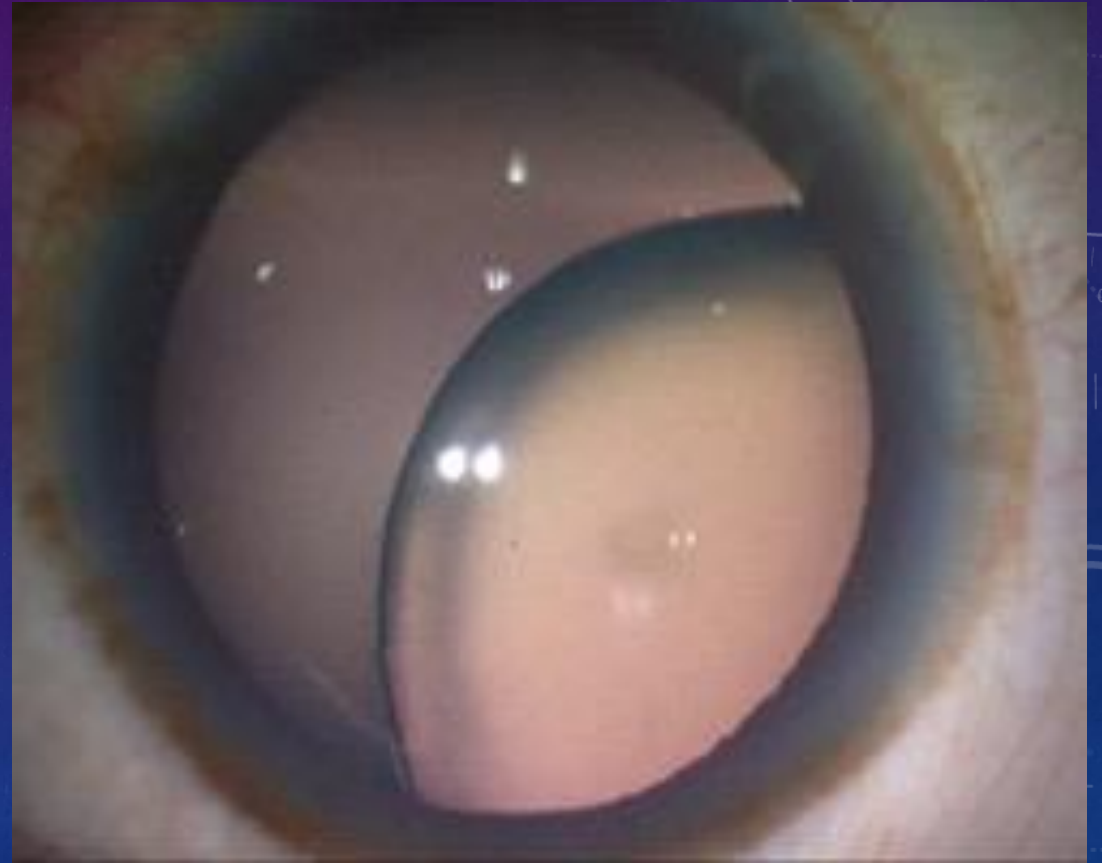


CHRONIC ANGLE CLOSURE GLAUCOMA



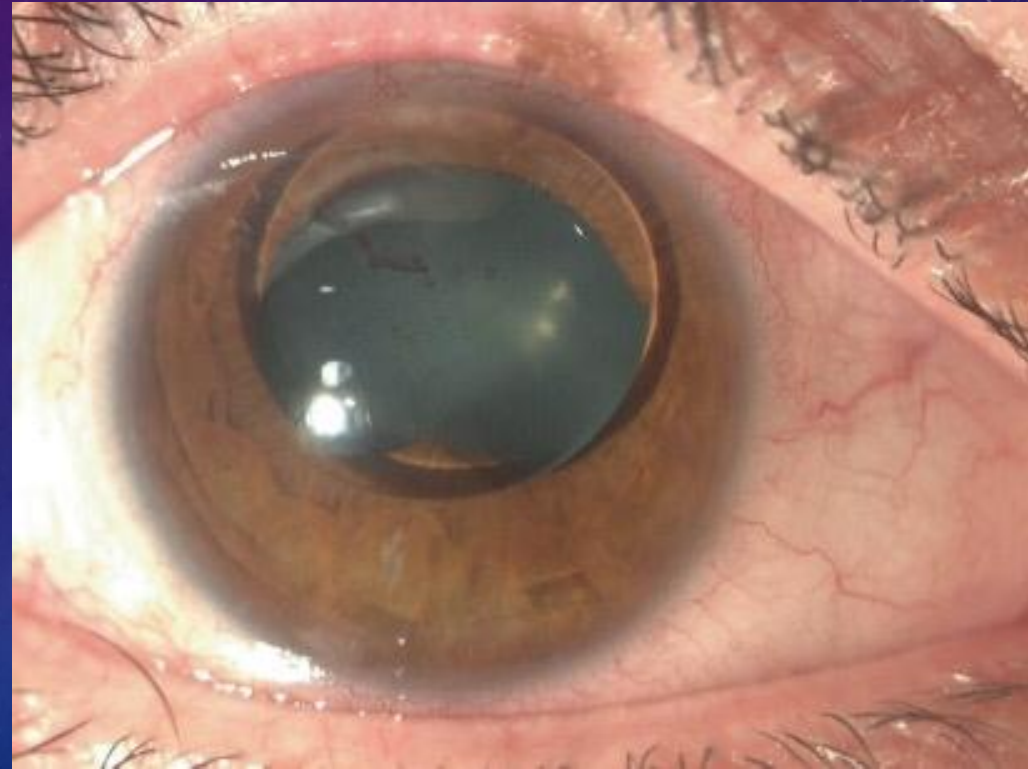
PUPILLARY BLOCK (SUBLUXED LENS)

- Ectopic lens :
- Familial with long list of etiologies ..Marfan , syphillis ,high myopia , mature cataract ,PXF
- Trauma



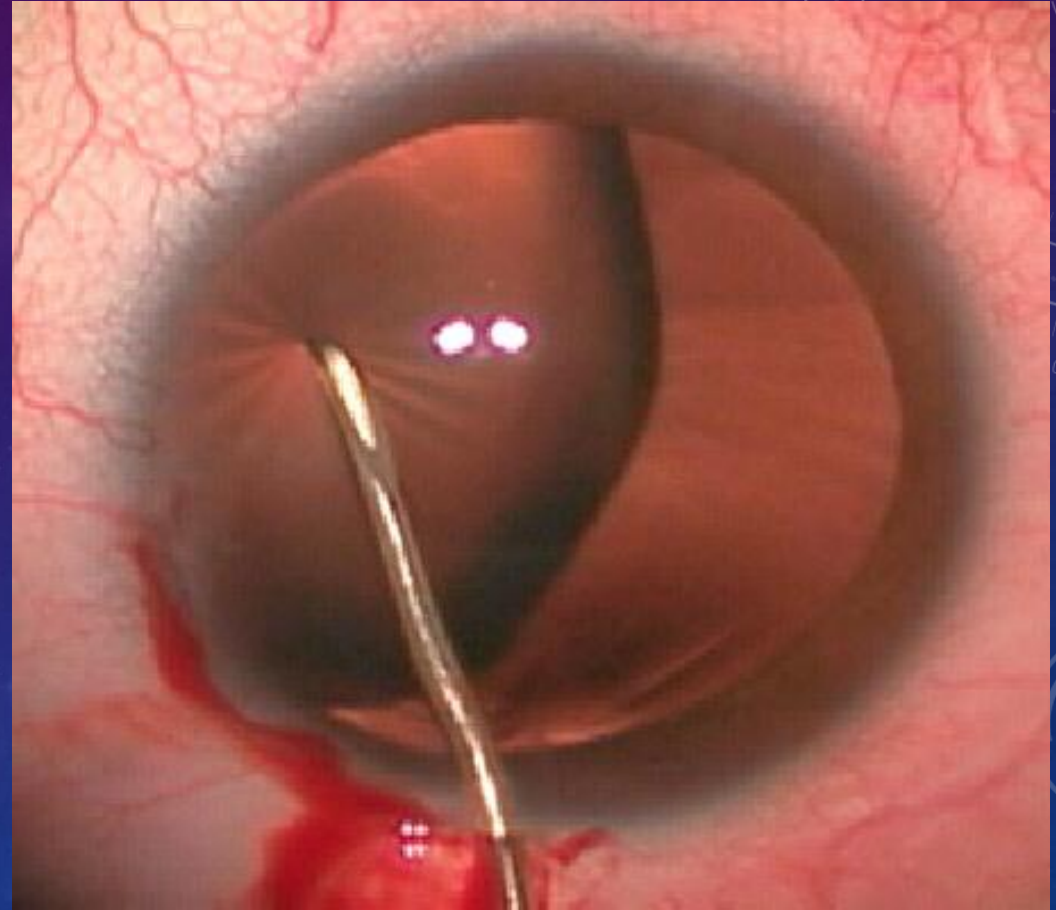
PUPILLARY BLOCK

- Lens can sublux into the AC
- Recurrent attacks can lead to PAS ,disc damage ,corneal injury



PUPILLARY BLOCK

- Rx :
- LPI or surgical PI
- Miotics ?
- Lens extraction

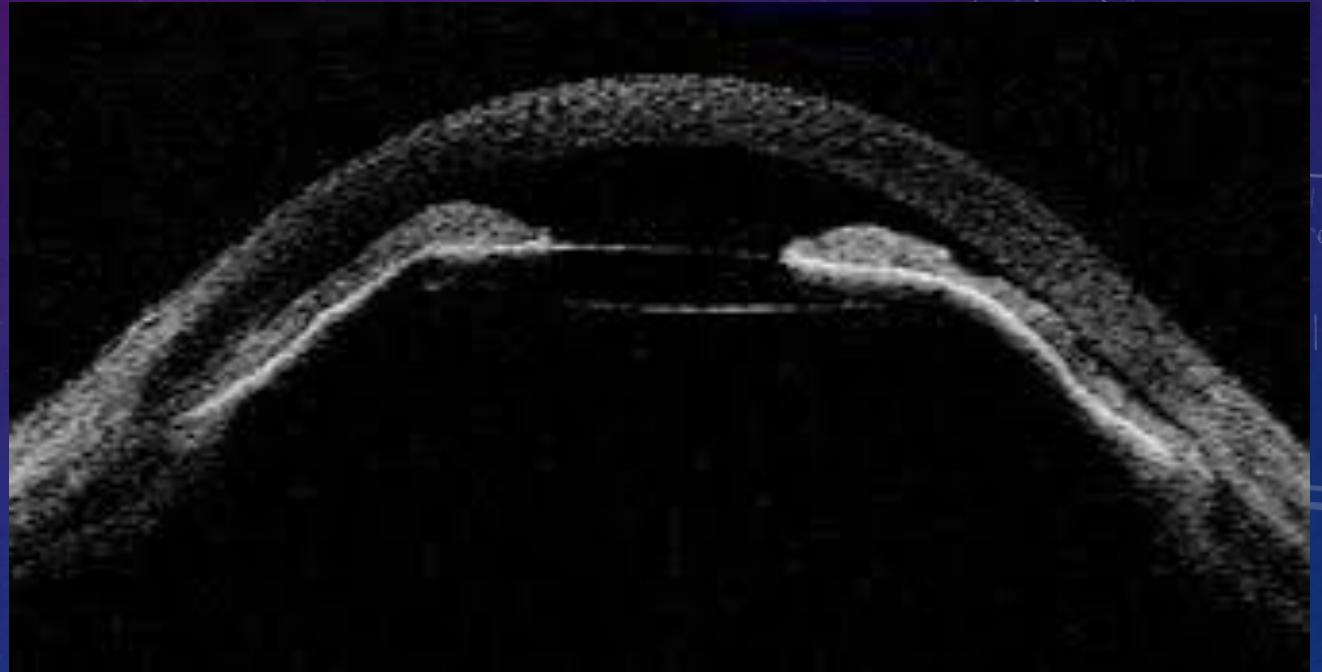


GLAUCOMA RELATED TO IOL

- Pupillary block
- UGH
- PDS

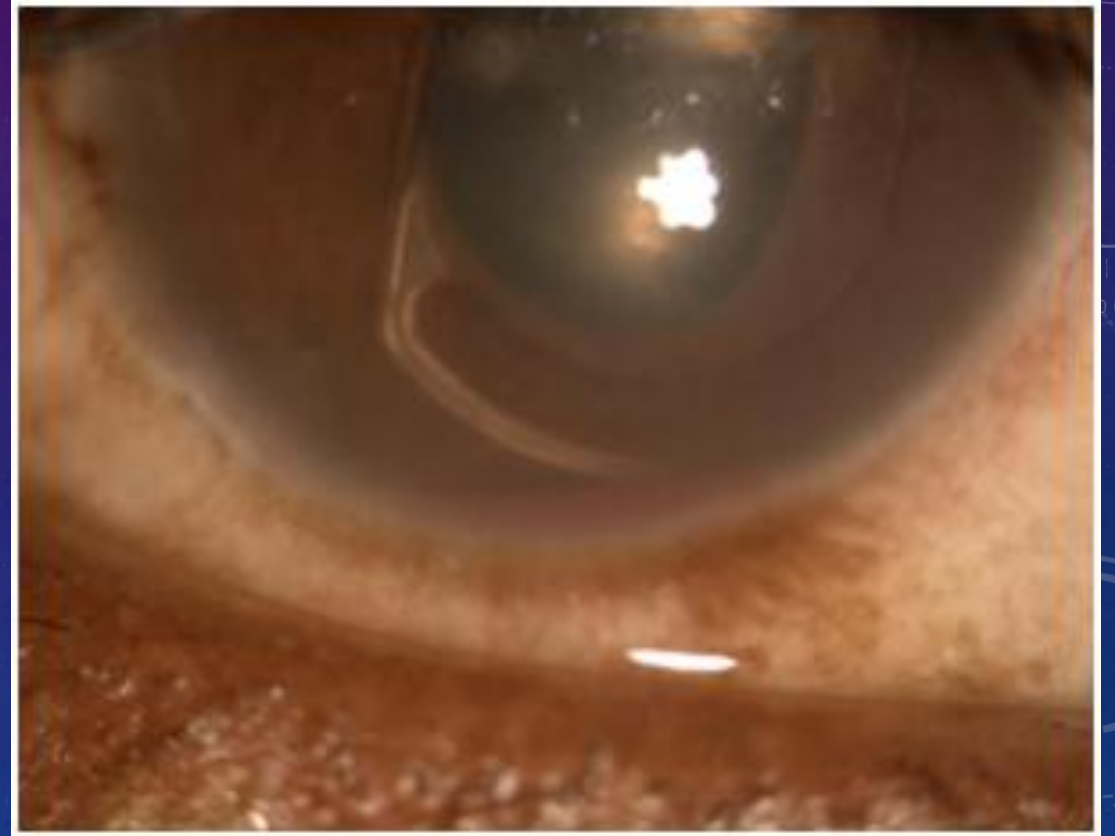
IOL RELATED GLAUCOMA

- IOL pupillary block



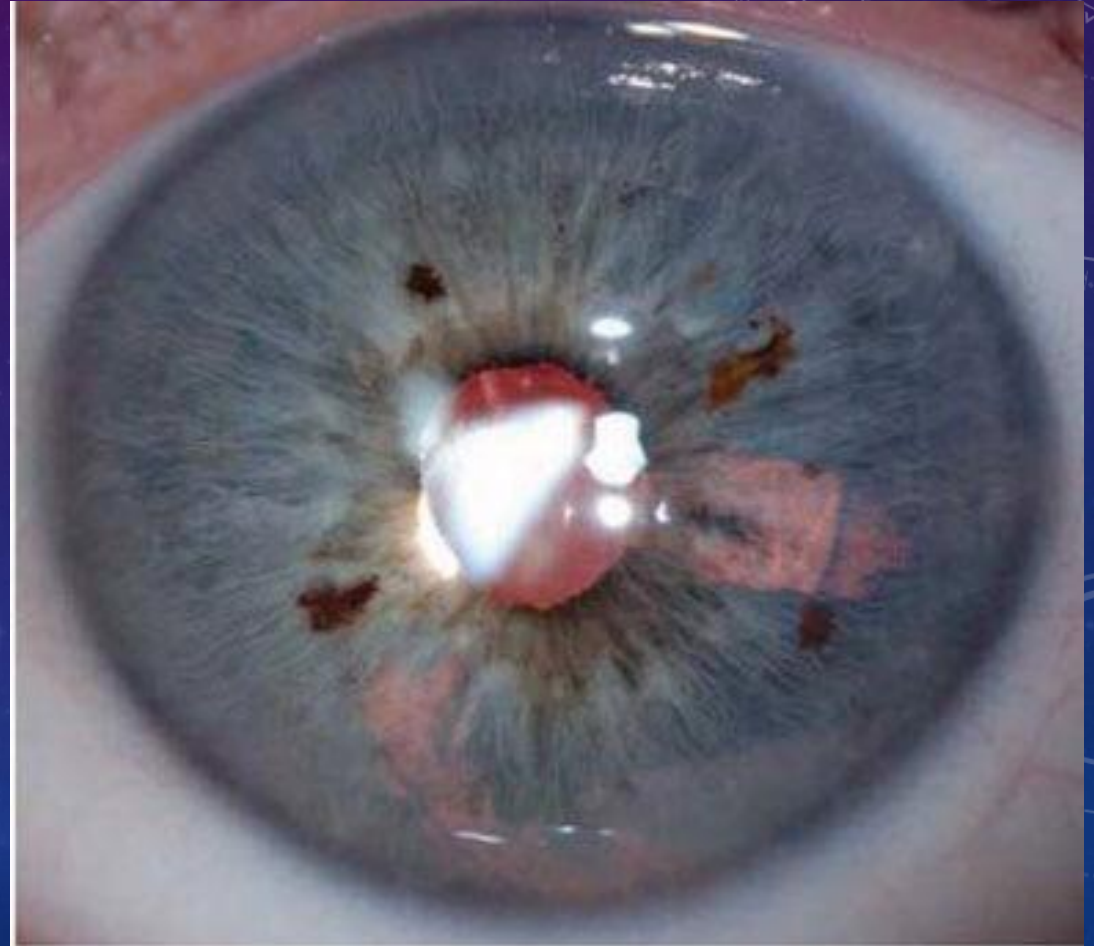
IOL RELATED GLAUCOMA

- UGH



IOL RELATED GLAUCOMA

- PDS





Thank you for your attention

Saladin Mugharbel MD